CASE REPORT

Heart transplant for multiple recurrences of familial cardiac myxomas in an adolescent patient: a case report and literature review

Thiyaphat Laohawetwanit[1*], Poonchavist Chantranuwatana[1], and Pat Ongcharit[2]

[1] *Department of Pathology, Faculty of Medicine, Chulalongkorn University, Bangkok, Thailand*
[2] *Division of Cardiothoracic Surgery, Department of Surgery, Faculty of Medicine, Chulalongkorn University, Bangkok, Thailand*

* Correspondence to: Thiyaphat Laohawetwanit, Department of Pathology, Faculty of Medicine, Chulalongkorn University, 1873 Rama 4 Road, Pathumwan, Bangkok 10330, Thailand. Email: thiyaphat@hotmail.com

Abstract

Cardiac myxoma is the most common primary cardiac neoplasm occurring in all age groups. After resection, familial cardiac myxoma is more likely to recur than that arises in sporadic fashion. In this report, we describe an adolescent patient experiencing multiple recurrences of cardiac myxomas and underwent heart transplant. This is the first report of such a case at our institution.

Keywords: cardiac myxoma; Carney complex; embolisation; heart transplant

Introduction

Primary cardiac tumours are rare, with an incidence rate of 0.0017% to 0.19% in unselected autopsies[1]. The majority of these tumours are benign. Rhabdomyomas and myxomas are the most common primary tumours of the heart in children and adults, respectively.

Cardiac myxoma is the most common primary neoplasm of the cardiac muscle commonly arising from the endocardium. It can be detected in all age groups (prenatally to 97 years old). Mean age at presentation is between the fourth and seventh decades of life. More than 90% of cardiac myxomas occur sporadically. Less than 10% of them are associated with Carney complex (myxoma syndrome), which is an autosomal dominant pattern of inheritance. This tumour is commonly seen in younger patients without sex predominance[2].

High recurrence rate is reported for familial cardiac myxomas; nevertheless, multiple recurrences are very rare[3]. In this report, we describe a patient having multiple recurrences of multicentric cardiac myxomas and underwent cardiac transplantation. This is the first report of such a case at King Chulalongkorn Memorial Hospital. The study was approved by the institute's ethics committee (COA No. 293/2018 and IRB No. 109/61).

Case report

In 2010, a 10-year-old girl was referred to our hospital due to a mass in left atrium and congestive heart failure. Two months earlier, she developed subacute progressive dyspnoea, which was worsened by exertion. She also had orthopnoea and chest tightness. Initial physical examination revealed right ventricular heave and thrill, pansystolic murmur grade 4/6 at apex and hepatosplenomegaly. Chest x-ray displayed cardiomegaly and pulmonary venous congestion. Neither rash nor endocrinopathy was identified. Her father had recurrent cardiac myxoma with cerebral embolic stroke. He underwent two episodes of surgical removal in 2003 and 2010. Other family members were healthy. She was diagnosed as familial cardiac myxoma. Surgical removal of the mass was performed.

Two years after initial resection of the mass, she developed acute onset of right leg pain and pallor along with new onset of hypertension. Five intracardiac masses were also identified. Two of them were in left atrium. Others were in left ventricle, pulmonary vein and interatrial septum. She was diagnosed as recurrent cardiac myxomas, acute right superficial femoral artery and bilateral renal artery embolism with bilateral renal infarction. Surgical removal of masses, fasciotomy and embolectomy were performed. Bilateral renal infarction was clinically improved by medical treatment. A right ventricular mass was noted in 2 years after the second episode of surgical removal. Excision was done. In three years afterward, she developed multiple intracardiac masses and underwent heart transplantation.

During the course of gross examination, six intramural masses (0.8 – 3.5 cm in the greatest dimension) are identified (*Figure 1*). Four of them are in the right ventricle. One of them is in

the left atrium. The other mass is in the left ventricle. All of these masses are of solid subtype showing globular, with a smooth and shiny surface. The cut surface is variegated. Whereas most of them show mucoid appearance with tan white cut surface, some of them displayed dark red discolouration (*Figure 2*).

Microscopically, these masses reveal several clusters of myxoma cells, which are characterised by cytologically bland, plump spindle cells possessing oval nuclei and eosinophilic cytoplasm. These cells are around small blood vessels which are surrounded by oedematous stroma (*Figure 3*).

After the patient had undergone heart transplantation, the clinical course was uneventful. Nine months later, she stopped immunosuppressive agents by herself and developed subacute progressive dyspnoea. Initial investigation revealed markedly diminished left ventricular ejection fraction. She also experienced acute acalculous cholecystitis with septic shock. Finally, she passed away.

Her body was sent for autopsy. The heart shows multiple foci of myocardial necrosis with adjacent loose fibrocollagenous stroma containing some lymphocytes (*Figure 4*). These lesions account for approximately 30% of the myocardium. These lymphocytes reveal CD3 immunoreactivity. Subendocardial myocytolysis is occasionally seen. The aorta and coronary arteries are unremarkable. Scattered fibrin thrombi are also observed within pulmonary capillaries and glomeruli.

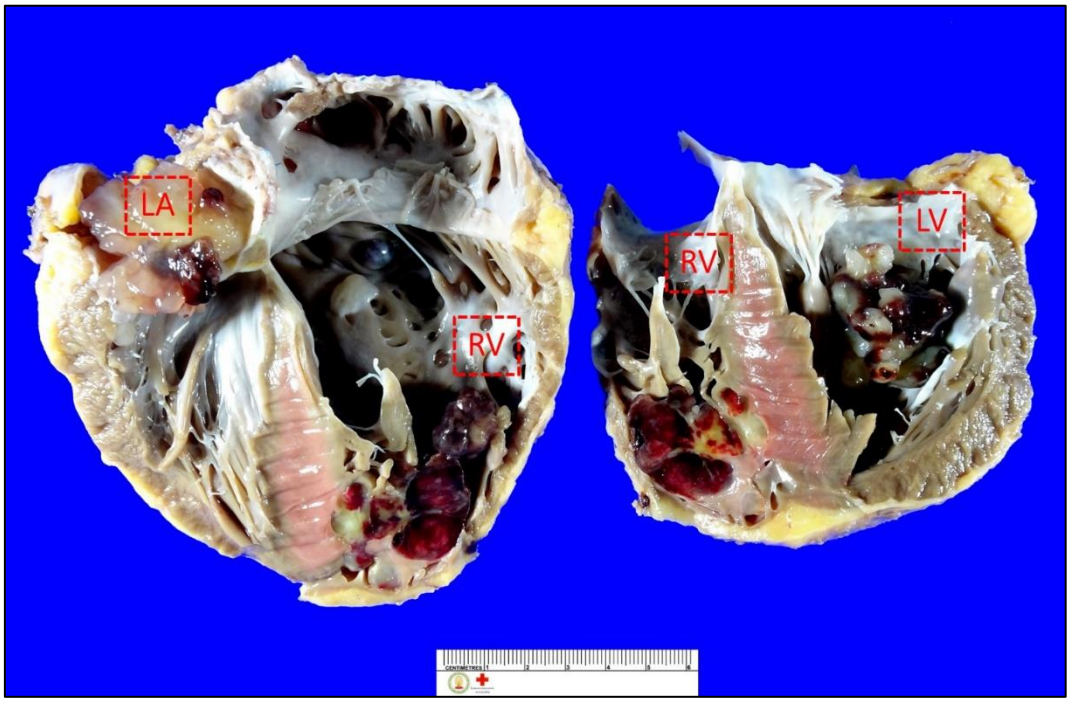

Figure 1 Multiple cardiac myxomas in the explanted (native) heart (*LA = Left atrium; RV = Right ventricle; and LV = Left ventricle*).

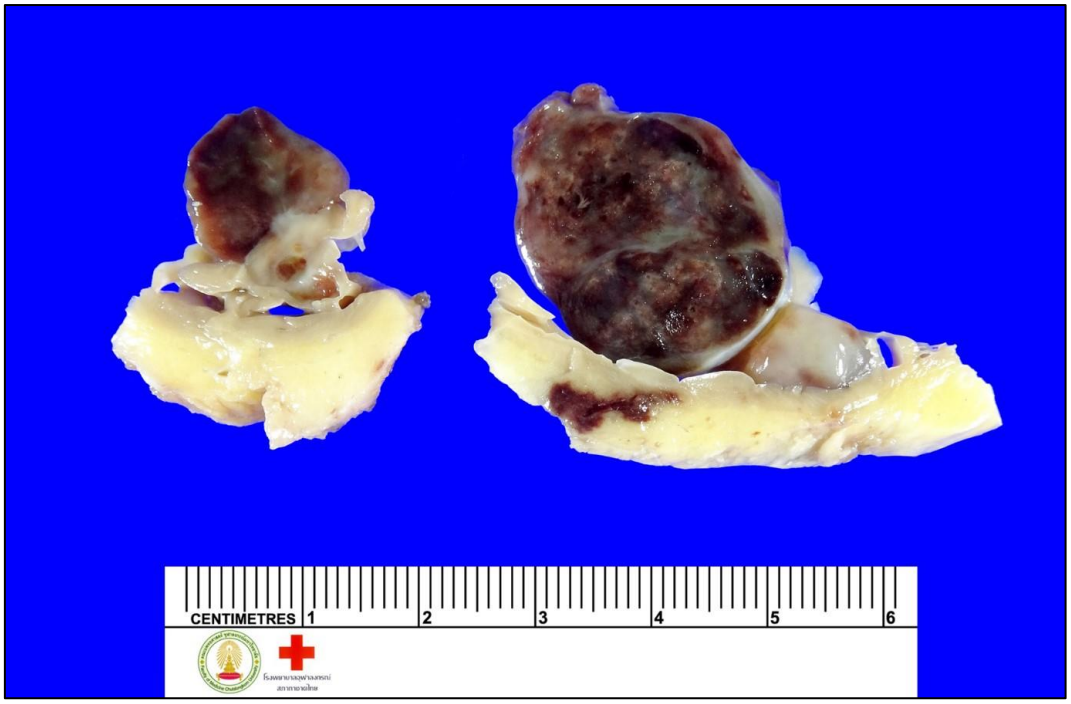

Figure 2 Excised solid myxoma.

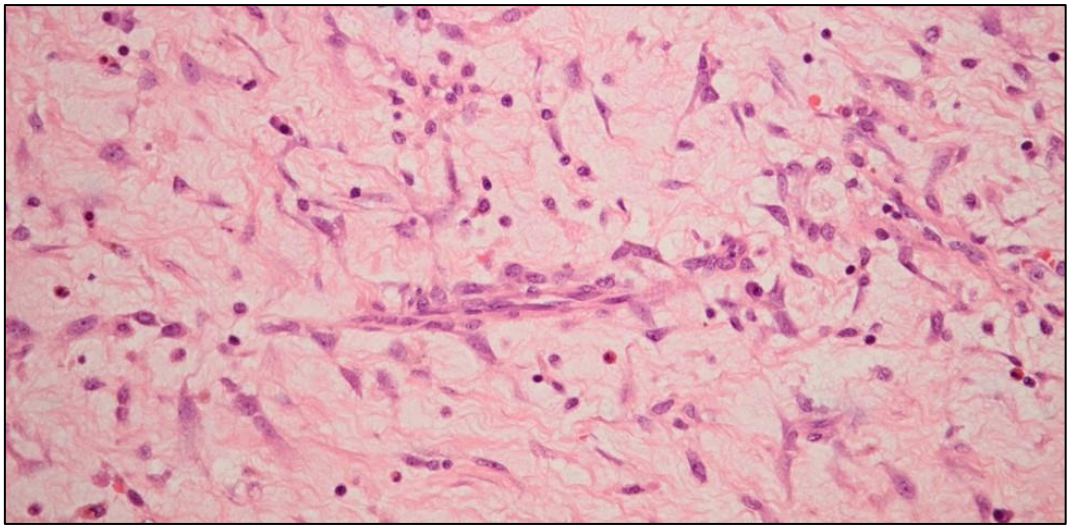

Figure 3 Histologic section of a myxoma (*Haematoxylin and eosin, x400*).

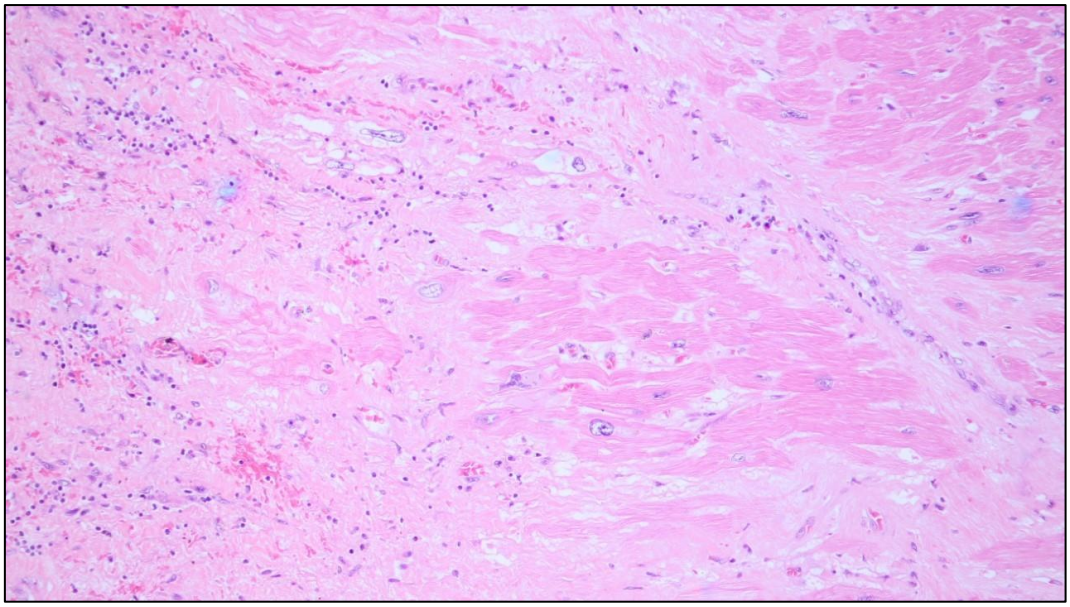

Figure 4 Autopsy finding of the heart (*Haematoxylin and eosin, x200*).

Discussion

Primary cardiac neoplasms are very uncommon in children and adolescents. The clinical presentation is varied, including dyspnoea, chest pain, and cyanosis. Cardiac myxoma is the one of the most common cardiac neoplasms in this subpopulation. According to a systematic review, its prevalence is highest in 10 – 18 years of age. After being resected, this tumour rarely recurred[4].

Less than 10% of cardiac myxomas are presented in the context of Carney complex[2]. Its diagnostic criteria are listed in *Table 1*[3]. The patient and her father were presented with cardiac myxomas which were histologically proven. Neither endocrinopathy nor spotty skin pigmentation was identified. This is consistent with the diagnostic criteria of Carney complex. Cardiac myxomas occur at a younger age comparing with those of sporadic cases, multicentrically, and in any, or all, cardiac chambers.

After resection, cardiac myxoma arising in the setting of Carney complex sometimes recurs. Its recurrence rate is approximately 22% comparing with that of 3% observed in non-syndromic tumour[5]. Other risk factor for tumour recurrence is margin status. Embolisation is associated with cardiac myxoma which is villous, soft gelatinous and less than 4.5 cm in the greatest dimension[2,6]. Embolisation to both systemic and pulmonary circulation can occur. Upon examination of the masses, they are soft gelatinous and less than 4.5 cm in the greatest dimension. The patient also developed splenic infarction, bilateral renal infarction and peripheral arterial occlusion.

Table 1 Diagnosis of Carney complex needs the presence of two manifestations of the disease listed or one of these major criteria and one of the supplemental criteria.

Major criteria
1. Spotty skin pigmentation with a typical distribution (lips, conjunctiva and inner or outer canthi, vaginal and penile mucosa)
2. Myxoma (cutaneous and mucosal)
3. Cardiac myxoma
4. Breast myxomatosis or fat-suppressed magnetic resonance imaging findings suggestive of this diagnosis
5. Primary pigmented nodular adrenocortical disease (PPNAD) or paradoxical positive response of urinary glucocorticosteroids to dexamethasone administration during Liddle's test
6. Acromegaly due to GH-producing adenoma
7. Large-cell calcifying Sertoli cell tumour (LCCSCT) or characteristic calcification on testicular ultrasonography
8. Thyroid carcinoma or multiple, hypoechoic nodules on thyroid ultrasonography, in a young patient
9. Psammomatous melanotic schwannoma
10. Blue nevus, epithelioid blue nevus (multiple)
11. Breast ductal adenoma (multiple)
12. Osteochondromyxoma
Supplemental criteria
1. Affected first-degree relative
2. Inactivating mutation of *PRKAR1A* gene

Multiple recurrent familial cardiac myxomas are previously reported (*Table 2*)[5,7-20]. These tumours usually occurred in female with varied age of onset, ranging from 10 to 73 years old. The most common site at initial presentation was left atrium. All of these patients were treated with tumour resection. None of them underwent cardiac transplantation. Cardiac myxoma is a rare underlying heart disease underwent heart transplant. Comparing with the previously reported cases, the current case was presented with the early-onset disease. Among Asian countries, common causes of end-stage heart diseases to undergo heart transplant were comparable with those of the global registry. Ischaemic cardiomyopathy, non-ischaemic cardiomyopathy and valvular heart disease were leading causes for recipients to undergo heart transplant, respectively[21].

Table 2 Reported cases on multiple recurrences of familial cardiac myxomas.

Author	Year	Gender	Age (Years)	Size (cm)	Location	Diagnosis	Presentation	Surgical therapy
Grauer[7]	1983	F	16	N.A.	LA	Cath	Splenic infarct	Endothelial stripping
			18	N.A.	LA	Cath	Cerebral infarct, hemiparesis	Endothelial stripping
			20	N.A.	RA, LA	Cath	Pneumonia	Resection
			29	N.A.	RA	Cath	N.A.	Resection, atrial septectomy
Gray[8]	1985	F	18	N.A.	LA	Cath	Bilateral claudication, dyspnoea, haemoptysis	Resection
			29	N.A.	LA, RA	Cath	Murmur, arm claudication	Resection, ASD repair
			42	N.A.	RV, TV, LA	Cath, echo	Dyspnoea, malaise, murmur	Resection, TVR, ASD repair
Wilsher[9]	1986	F	21	N.A.	RA	Angiography	Chest pain, dyspnoea, malaise	Resection
			29	8	LA	Cath	Cerebral infarct, left brachial artery embolism	Resection
Haught[10]	1991	F	26	N.A.	RA	N.A.	Preoperative evaluation for hysterectomy	Resection
			29	N.A.	RA	Echo	Haemoptysis	Resection
			32	N.A.	LA	Echo	Congestive heart failure	Resection
			34	1.5	LA	Echo	Screening	Resection
Singh[11]	1996	F	32	N.A.	RA	Cath	Fatigue, weight loss, pedal oedema	Resection
			40	N.A.	LA	Echo	Pulmonary embolism	Resection
			46	N.A.	LA	Echo	Tachycardia, weight loss	Resection
		M	21	1.5	LV (multiple)	Echo	Cerebral infarct	Resection
			24	N.A.	RA	Echo	Intermittent numbness	Resection, ASD repair
Mahilmaran[12]	2003	M	12	8, 3	RA, LA	Echo	Swelling of legs and face, abdominal distention, breathlessness	Resection, ASD repair
			14	4	MV	Echo	Screening	Not done (psychiatric problem)
Kojima[13]	2005	F	39	3.8	LA	Echo	Cough, dyspnoea	Resection
			43	N.A.	LA, LV (multiple)	Echo	Screening	Resection

Note: *ASD = Atrial septal defect; Cath = Cardiac catheterisation; CT = Computed tomography; Echo = Echocardiography; F = Female; LA = Left atrium; LV = Left ventricle; M = Male; MRI = Magnetic resonance imaging; N.A. = Not applicable; RA = Right atrium; RV = Right ventricle; TV = Tricuspid valve; and TVR = Tricuspid valve replacement*

Table 2 (Continued) Reported cases on multiple recurrences of familial cardiac myxomas.

Author	Year	Gender	Age (Years)	Size (cm)	Location	Diagnosis	Presentation	Surgical therapy
Akbarzadeh[14]	2005	F	17	N.A.	LA	N.A.	Cerebral infarct	Resection
			33	N.A.	LA	N.A.	N.A.	Resection
			35	N.A.	LA (multiple), LV	Echo	Dyspnoea, paresis of the left hand	Resection
Turhan[15]	2008	F	10	N.A.	LA	Echo	N.A.	Resection
			14	1.4	LA	Echo	Screening	Follow-up
			42	N.A.	LA	N.A.	N.A.	Resection
			44	N.A.	LA	N.A.	N.A.	Resection
			46	5.7	LA	Echo	Screening	Resection
Roy[16]	2011	F	31	N.A.	LA	N.A.	N.A.	Resection
			38	2.5, 4	LA, RA	Echo, MRI	Visual disturbance	Resection, ASD repair
Cao[17]	2011	F	21	4	LA	Echo	N.A.	Resection
			26	4, 0.4	LA (x2)	Echo	Dyspnoea, palpitation and fatigability	Resection
Tamura[18]	2014	F	20	N.A.	LA	N.A.	N.A.	Resection
			28	N.A.	LA	N.A.	N.A.	Resection
			45	N.A.	RV	Echo	Loss of consciousness, infective endocarditis	Resection, tricuspid valve annuloplasty
Azzam[19]	2014	M	36	N.A.	LA	N.A.	N.A.	Resection
			40	N.A.	LA	Echo, CT	N.A.	Resection
			41	N.A.	LA	Echo, CT	N.A.	Resection
			51	3	LA	Echo, CT	Screening	Resection
Kwon[5]	2016	F	14	N.A.	RA, LA	N.A.	N.A.	Resection, ASD repair
			24	N.A.	LA, LV	N.A.	N.A.	Resection, ASD repair
			40	N.A.	RA	N.A.	N.A.	Resection, ASD repair
			46	10	RA	Echo, CT	Chest discomfort, dyspnoea	Resection

Note: *ASD = Atrial septal defect; Cath = Cardiac catheterisation; CT = Computed tomography; Echo = Echocardiography; F = Female; LA = Left atrium; LV = Left ventricle; M = Male; MRI = Magnetic resonance imaging; N.A. = Not applicable; RA = Right atrium; RV = Right ventricle; TV = Tricuspid valve; and TVR = Tricuspid valve replacement*

Table 2 (Continued) Reported cases on multiple recurrences of familial cardiac myxomas.

Author	Year	Gender	Age (Years)	Size (cm)	Location	Diagnosis	Presentation	Surgical therapy
Schmidt[20]	2017	M	73	N.A.	LA	N.A.	N.A.	N.A.
			78	N.A.	Intra-atrial septum	Echo	Visual loss of right eye, pre-syncopal episodes	Resection
Current case	2018	F	10	5.5	LA	Echo	Congestive heart failure	Resection
			12	0.5 – 4.5	LA (x2), LV, pulmonary vein, interatrial septum	Echo	Acute arterial occlusion	Resection, splenectomy, fasciotomy, embolectomy
			14	6	RV	Echo	Screening	Resection
			17	0.8 – 3.5	RV (x4), LA, LV	Echo	Screening	Heart transplant

Note: *ASD = Atrial septal defect; Cath = Cardiac catheterisation; CT = Computed tomography; Echo = Echocardiography; F = Female; LA = Left atrium; LV = Left ventricle; M = Male; MRI = Magnetic resonance imaging; N.A. = Not applicable; RA = Right atrium; RV = Right ventricle; TV = Tricuspid valve; and TVR = Tricuspid valve replacement*

Historically, we initiated a heart transplant program in 1987 with our first orthotopic heart transplant in December 1988, which was also the first case in Southeast Asia[22]. According to Thai Transplantation Society report, intrathoracic organ transplantation has been most frequently performed at King Chulalongkorn Memorial Hospital since 2008[23]. The presented case is the first case of end-stage heart disease due to multiple recurrences of familial cardiac myxomas to undergo heart transplant at our institution.

Conclusions

We presented a case with multiple recurrences of familial cardiac myxomas who underwent heart transplant at our institution. Multifocal and recurrent cardiac myxomas seem more common in younger age group who has a family history of tumour. After nine months of heart transplantation, she passed away as a result of acute cellular rejection and septic shock.

References

(1). Reynen K. Cardiac myxomas. N Engl J Med. 1995;333(24):1610-7.
(2). Travis WD, Brambilla E, Burke A, Marx A, Nicholson AG. WHO Classification of Tumours of the Lung, Pleura, Thymus and Heart. Lyon: International Agency for Research on Cancer; 2015.
(3). Stratakis CA, Kirschner LS, Carney JA. Clinical and molecular features of the Carney complex: diagnostic criteria and recommendations for patient evaluation. J Clin Endocrinol Metab. 2001;86(9):4041-6.
(4). Tzani A, Doulamis IP, Mylonas KS, Avgerinos DV, Nasioudis D. Cardiac Tumors in Pediatric Patients: A Systematic Review. World J Pediatr Congenit Heart Surg. 2017;8(5):624-32.
(5). Kwon OY, Kim GJ, Jang WS, Lee YO, Cho JY, Lee JT. Fourth Recurrence of Cardiac Myxoma in a Patient with the Carney Complex. Korean J Thorac Cardiovasc Surg. 2016;49(2):119-21.
(6). Wang Z, Chen S, Zhu M, Zhang W, Zhang H, Li H, et al. Risk prediction for emboli and recurrence of primary cardiac myxomas after resection. J Cardiothorac Surg. 2016;11:22.
(7). Grauer K, Grauer MC. Familial atrial myxoma with bilateral recurrence. Heart Lung. 1983;12(6):600-2.
(8). Gray IR, Williams WG. Recurring cardiac myxoma. Br Heart J. 1985;53(6):645-9.
(9). Wilsher ML, Roche AH, Neutze JM, Synek BJ, Holdaway IM, Nicholson GI. A familial syndrome of cardiac myxomas, myxoid neurofibromata, cutaneous pigmented lesions, and endocrine abnormalities. Aust N Z J Med. 1986;16(3):393-6.
(10). Haught WH, Alexander JA, Conti CR. Familial recurring cardiac myxoma. Clin Cardiol. 1991;14(8):692-5.6.

(11). Singh SD, Lansing AM. Familial cardiac myxoma--a comprehensive review of reported cases. J Ky Med Assoc. 1996;94(3):96-104.
(12). Mahilmaran A, Seshadri M, Nayar PG, Sudarsana G, Abraham KA. Familial cardiac myxoma: Carney's complex. Tex Heart Inst J. 2003;30(1):80-2.
(13). Kojima S, Sumiyoshi M, Watanabe Y, Suwa S, Matsumoto M, Nakata Y, et al. A Japanese case of familial cardiac myxoma associated with a mutation of the PRKAR1alpha gene. Intern Med. 2005;44(6):607-10.
(14). Akbarzadeh Z, Esmailzadeh M, Yousefi A, Safaei A, Raisi K, Sharifi F. Multicentric familial cardiac myxoma. Eur J Echocardiogr. 2005;6(2):148-50.
(15). Turhan S, Tulunay C, Altin T, Dincer I. Second recurrence of familial cardiac myxomas in atypical locations. Can J Cardiol. 2008;24(9):715-6.
(16). Shetty Roy AN, Radin M, Sarabi D, Shaoulian E. Familial recurrent atrial myxoma: Carney's complex. Clin Cardiol. 2011;34(2):83-6.
(17). Cao H, Wu Y, Zhu J, Chen Y. Familial cardiac myxoma with multifocal recurrences: a case report and review of the literature. J Biomed Res. 2011;25(5):368-72.
(18). Tamura Y, Seki T. Carney complex with right ventricular myxoma following second excision of left atrial myxoma. Ann Thorac Cardiovasc Surg. 2014;20 Suppl:882-4.
(19). Azzam R, Abdelbar A, Yap KH, Abousteit A. Carney complex: fourth time excision of recurrent atrial myxoma via left thoracotomy. BMJ Case Rep. 2014;2014.
(20). Schmidt C, Doi A, Ura M, Cole C, Mundy J. Familial Atrial Myxoma: Three Related Cases at an Australian Tertiary Institution. Ann Thorac Cardiovasc Surg. 2017;23(4):203-6.
(21). Krittayaphong R, Ariyachaipanich A. Heart Transplant in Asia. Heart Fail Clin. 2015;11(4):563-72.
(22). Ongcharit P, Wongkietkachorn K, Sritangsirikul S, Namchaisiri J, Singhatanatkit S, Luengtaviboon K, et al. Heart transplantation 1987- 2007: 20 years' experience at Chulalongkorn hospital. Transplant Proc. 2008;40(8):2591-3.
(23). Thai-transplant.org. 2016 Annual Report of Organ Transplantation in Thailand [Internet]. 2016 [cited 27 January 2018]. Available from: http://www.thai-transplant.org/pic/File/ Translate%20Registry%202016%20_English_.pdf.