Asian Archives of Pathology 2013; Vol. 9 No.1, 21-34

Case report

Primary Testicular NK/T-cell Lymphoma presented as testicular abscess: A Case Report and Literature Review of 33 cases

Sanya Sukpanichnant • Yingyong Chinthammitr • Naravat Poungvarin

Department of Pathology, Faculty of Medicine Siriraj Hospital, Mahidol University, Bangkok 10700, Thailand

Corresponding author: Sanya Sukpanichnant, M.D.,

Department of Pathology, Faculty of Medicine Siriraj Hospital, Mahidol University, Bangkok 10700, Thailand, Tel/Fax +66 2 411 4260 e-mail: sanya.suk@mahidol.ac.th

Coauthors and names of the department and institution:

Yingyong Chinthammitr, M.D.

Department of Medicine, Faculty of Medicine Siriraj Hospital, Mahidol University, Bangkok, Thailand

Naravat Poungvarin, M.D., Ph.D.

Department of Clinical Pathology, Faculty of Medicine Siriraj Hospital, Mahidol University, Bangkok, Thailand

ABSTRACT

Primary testicular NK/T-cell lymphoma is rare. We report a 61-year-old Thai man who presented with right testicular abscess clinically but tissue obtained from incision and drainage was proven to be NK/T-cell lymphoma. The lymphoma cells were small to medium in size and showed angiocentricity with associated necrosis. The lymphoma cells were CD3+ (cytoplasmic), CD43+, CD56+, TIA-1+, Ki-67+ (nearly 100%) and EBV encoded RNA (EBER)+. Clinical staging was IE. CHOP chemotherapy and intrathecal methotrexate for primary CNS prophylaxis were administered with partial reduction of the testicular mass. However, 5.5 months after diagnosis, the patient developed left testicular enlargement and left facial palsy caused by leptomeningeal involvement. The patient died of progressive disease 9 months after diagnosis. The clinical course in this patient was aggressive, similar to those described in the literature review except for the uncommon CNS involvement. Based on 19 cases of primary testicular lymphoma (including the present case) and 15 cases of testicular involvement by NK/T-cell lymphoma elsewhere, the former seem to be less aggressive than the latter but the difference is not statistically significant in either overall median survival (32 vs. 16 weeks, $p = 0.086$) or mean survival (29.4 vs. 17.9 weeks, $p = 0.083$).

Keywords: Testicular lymphoma • testicular abscess • extranodal • NK/T-cell lymphoma • EBER • CNS involvement

INTRODUCTION

Testicular lymphoma is uncommon, accounting for only 1% of extranodal lymphoma in Thailand [1]. At Siriraj Hospital, more than 80% of testicular lymphoma cases were diffuse large B-cell lymphoma while only 9% were mature T-cell lymphoma. Only a small number of testicular involvement by nasal-type extranodal NK/T-cell lymphoma have been reported in the English literature. No primary testicular lymphoma case was included in the study of 67 cases of extranodal NK/T-cell lymphoma previously reported from Thailand [2]. In the English literature, primary testicular lymphoma of any subtypes is uncommon and it mostly presents as stage I or II disease (approximately 75% of the patients). However, it has been well known for aggressiveness in term of systemic disease at relapse (30-40% of cases). CNS involvement, in the form of brain parenchyma, leptomeninges or both, is the most common site at relapse in nearly half of the patients [3-5]. We hereby report a case of primary testicular NK/T-cell lymphoma who first presented as testicular abscess and review the English literature to emphasize the clinical importance of this particular type of lymphoma.

CLINICAL HISTORY

A previously healthy, 61-year-old, Thai man had presented with a right testicular mass for 4 months and later he experienced testicular pain and fever. He was diagnosed as having testicular abscess at a local hospital. Incision and drainage (I&D) was performed and oral antibiotics were given. The tissue with some necrotic debris was obtained and submitted for microbiological study and pathologic examination. The microbiological study yielded no growth of microorganism but the pathologic diagnosis given by a pathologist at a private pathology laboratory based on histologic findings only was malignant round cell tumor, suspicious of malignant lymphoma. Immunohistochemistry was recommended for further evaluation. The patient was then referred to Siriraj Hospital for further management.

Three weeks after I&D, the patient attended the outpatient department service of the Division of Urology, Department of Surgery at Siriraj Hospital. No other significant clinical history was obtained except for night sweats. Physical examination revealed an enlarged right testis, measuring 15 cm. in maximal diameter. The small healed I&D wound was noted. No lymphadenopathy or organomegaly was detected. Complete blood count and blood chemistry results were within the normal ranges. The histologic sections and corresponding tissue blocks were submitted to the Department of Pathology for review. The diagnosis was extranodal NK/T-cell lymphoma, nasal type, according to the WHO classification (2008) [6].

Two weeks after the first visit at Siriraj Hospital, the patient underwent bone marrow examination and computed tomography (CT) of the chest and whole abdomen for clinical staging which corresponded to stage IE. Cerebrospinal fluid (CSF) was also obtained and no lymphoma cells were detected. The International Prognostic Index (IPI) was low (IPI = 1). So, 10 days after a definite diagnosis or 37 days after I&D, the patient received CHOP regimen and intrathecal methotrexate administration for primary CNS prophylaxis. The patient refused both orchiectomy and local radiotherapy. A week later, the right testicular mass reduced in size to 9x6 cm. Two weeks later, the ear, nose and throat (ENT) region was examined at the Department of Otolaryngology. No abnormalities were detected. Partial response to CHOP chemotherapy was obtained after the fourth course of CHOP as the right testicular mass reduced in size to 5.2 cm.

in maximal diameter. But, after the fifth course of chemotherapy, the right testicular mass grew up to 7 cm. and, 3 weeks after the seventh course of chemotherapy or 5.5 months after diagnosis, the patient developed generalized bone pain and additional left testicular enlargement to 10 cm. in maximal diameter. Oral prednisolone (20 mg./day) was given as a palliative treatment. Three days later, the patient developed left facial palsy caused by leptomeningeal involvement as lymphoma cells were detected in the CSF. He received palliative oral chemotherapy and further intrathecal therapy (hydrocortisone, methotrexate, and Ara-C) twice weekly without any improvement. A week later, CT of the brain revealed a subacute lacunar infarction at left basal ganglion and enhancing soft tissue lesions at both nasal cavities and paranasal sinuses. The patient also developed pain at both legs that progressed to be cauda equina syndrome, requiring urinary bladder catheter dwelling. During admission and while receiving palliative treatment, the patient developed febrile neutropenia and influenza A pneumonia but he recovered eventually from pneumonia. During this time, the right and left testes measured 6 cm. and 10 cm. in maximal diameter respectively. Local irradiation was given at both testes for a 10 day period and discontinued as the patient asked for only palliative care. He was discharged 7.5 months after diagnosis and received palliative medication including oral prednisolone (20 mg./day), morphine syrup and antipyretics. During this terminal phase, the patient had suffered from progressive fatigue, muscle pain, bone pain, anorexia and fever. He died of progressive disease 9 months after diagnosis at a local hospital.

MATERIALS AND METHODS

The provided paraffin-embedded formalin-fixed tissue block of the tissue obtained from I&D was used for histopathologic, histochemical, immunohistochemical, in situ hybridization (ISH) and molecular genetic studies. Standard hematoxylin & eosin-stained slide and PAS-stained slide were performed conventionally. Immunohistochemical staining and ISH for EBV-encoded RNA (EBER) were performed by Bench-Mark® XT autostainer (Roche Diagnostic). The authors could usefully provide more detail on antibody clones in dilutions in the Methods section. The remaining tissue in the block was used for molecular genetic studies for rearrangement of T-cell receptor (TCR) genes using BIOMED-2 multiplex PCR-based assay kit. The cytologic preparation was prepared from the provided CSF using cytospin technique.

RESULTS

The malignant round cells described in the original pathology report appeared to be small to medium-sized lymphoma cells, showing diffuse infiltration with angiocentricity and multifocal necrosis. Immunohistochemistry demonstrated that the lymphoma cells were CD3+ (cytoplasmic), CD43+, CD56+, TIA-1+ and Ki-67+ (nearly 100%). Other markers were negative including betaF-1, CD4, CD5, CD8, CD20, CD34, CD68, CD117, myeloperoxidase and TdT. Diffuse and strong positivity with in-situ hybridization for EBV RNA (EBER) was noted in the lymphoma cells. (Figure 1) Molecular genetic study for rearrangement of TCR genes was performed but the target fragment was not successfully amplified due to insufficient DNA quality. Finally, the diagnosis of extranodal NK/T-cell lymphoma, nasal type, was given according to the WHO classification (2008) [6]. Lymphoma cells were found in the CSF at the time of left facial palsy, indicating leptomeningeal involvement. Only few cells had few azurophilic granules. (Figure 2)

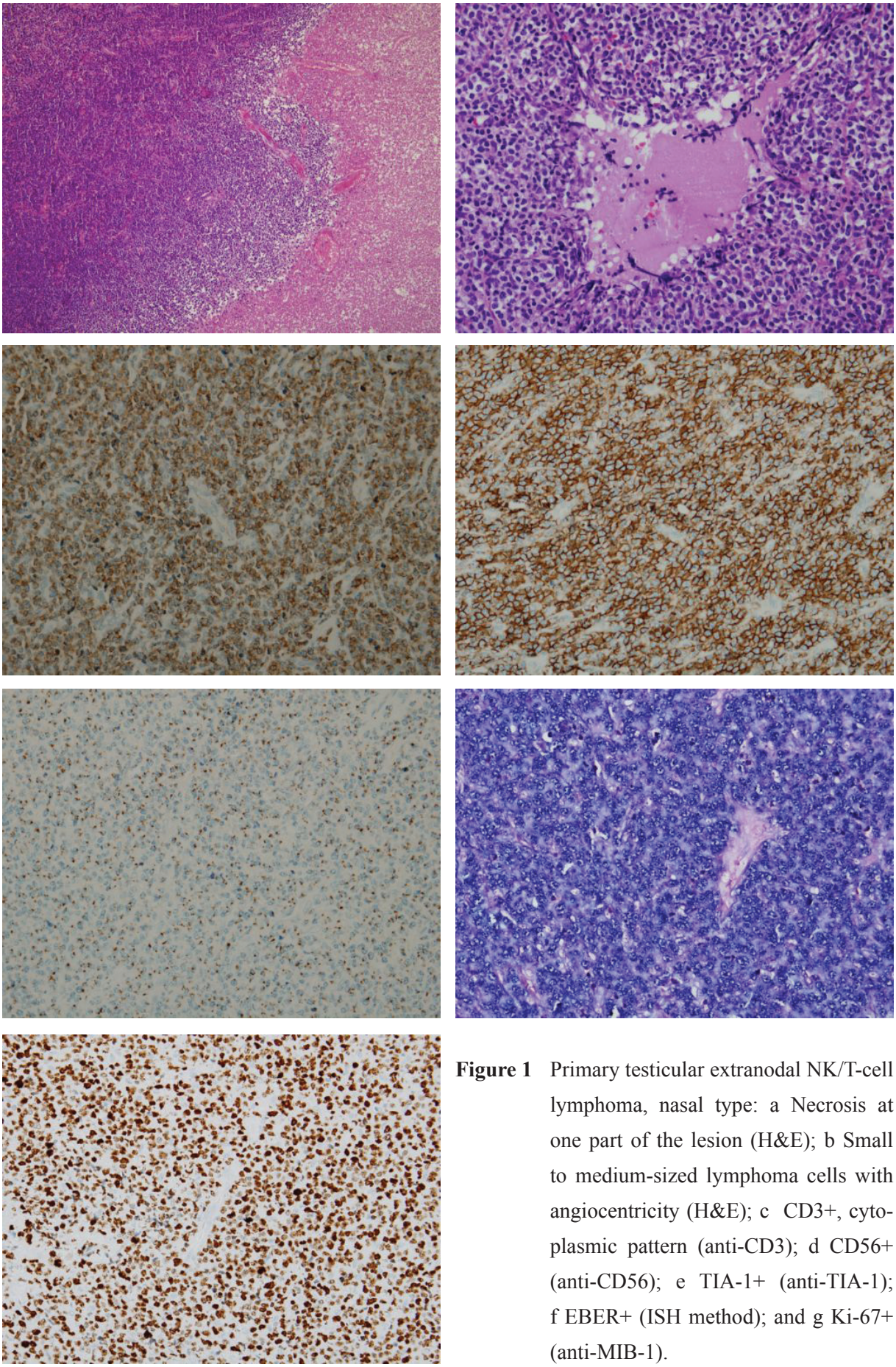

Figure 1 Primary testicular extranodal NK/T-cell lymphoma, nasal type: a Necrosis at one part of the lesion (H&E); b Small to medium-sized lymphoma cells with angiocentricity (H&E); c CD3+, cytoplasmic pattern (anti-CD3); d CD56+ (anti-CD56); e TIA-1+ (anti-TIA-1); f EBER+ (ISH method); and g Ki-67+ (anti-MIB-1).

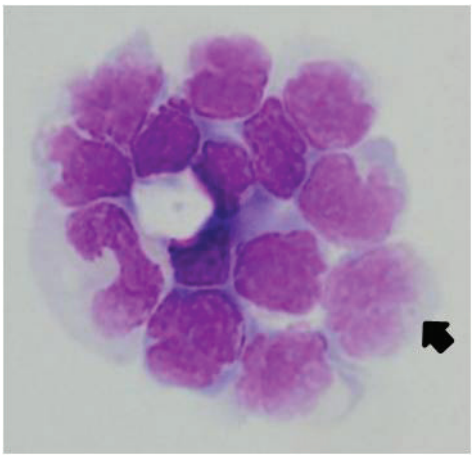

Figure 2 Lymphoma cells in the cerebrospinal fluid. Note the pleomorphic nuclei but few azulophilic granules (arrow).

DISCUSSION

The diagnosis of nasal-type NK/T-cell lymphoma requires the conventional approach according to the WHO classification (2008) [6]. After clinical staging work-up, the lesion was localized to the testis and the morphologic, immunophenotypic and genetic findings confirmed that this is primary testicular NK/T-cell Lymphoma. Azurophilic granules recognized in Wright or Diff-Quik stained cytologic preparation will be very helpful to indicate NK-cell or cytotoxic T-cell phenotype of the lymphoma cells despite the nuance of cytologic features including lymphoblastic, small, small to medium, medium, medium to large and large pleomorphic or anaplastic cells. Syncytial aggregates or small clusters of large pleomorphic cells can be seen in fine needle aspiration [7]. It is noteworthy to be aware that azurophilic granules may be found in only some of the lymphoma cells [8]. In this present case, azurophilic granules were hard to find in the CSF. In the histologic sections, the tissue necrosis caused by lymphoma cells infiltrating around the blood vessel (angiocentricity) as well as angiodestruction is a salient feature described in this particular type of lymphoma [6, 8]. But in some case reports, only coagulation necrosis and ulceration were described [9]. Softening of tissue following necrosis occurred in the testicular mass then led to the clinical impression of testicular abscess in the setting of a testicular mass with pain and fever as diagnosed at a local hospital in the present case. Thus, testicular lymphoma should be kept in mind when encountered with testicular abscess. Tissue obtained from incision and drainage should be submitted not only microbiological study but also pathologic examination.

The most common type of primary testicular lymphoma is diffuse large B-cell lymphoma (more than 90% of cases in most series). The less common types include extranodal NK/T-cell lymphoma and Burkitt lymphoma [3, 10]. CNS involvement with intracerebral, leptomeningeal or both involvements has been noted in up to 30% of patients with testicular B cell lymphoma [11]. Possibly similar to other testicular tumors, CNS metastasis in malignant lymphoma can occur through lymphatic drainage to the retroperitoneal lymph nodes, then to the posterior mediastinal or supraclavicular lymph nodes before spreading through the systemic circulation. Direct hematogenous spread to the brain is also possible

[12]. Blood-brain barrier (BBB) provides a sanctuary hiding place for lymphoma cells that spread to the CNS as most standard chemotherapeutic agents cannot penetrate across the BBB. So CNS becomes a common site of relapse after standard chemotherapy regimens. Prophylactic intrathecal chemotherapy or systemic chemotherapeutic agents that can penetrate across the BBB, including methotrexate and cytarabine, have been recommended to prevent leptomeningeal or CNS involvement [3, 5]. Prophylactic intrathecal chemotherapy alone, however, may not be able to prevent brain parenchymal involvement at relapse; thus whole brain radiotherapy or systemic chemotherapy are needed [3]. While CNS involvement is quite common in primary testicular large B-cell lymphoma, CNS involvement in primary testicular NK/T-cell lymphoma was reported in only 1 case in the literature proven by Kim and colleague [13] and in the present case. There were 2 other cases in the literature mentioned about encephalitis [14] and intracranial bleeding [15] but they did not confirm whether there was genuine CNS involvement or not. At this point, only 2 out of 19 cases of primary testicular NK/T-cell lymphoma in the literature (including the present case) had CNS involvement (10.5%).

From the compilation of three large series of 98 cases of nasal-type extranodal NK/T-cell lymphoma (non-nasal site) from Hong Kong, Singapore and Korea, only 9 cases had testicular involvement (9.2%) or approximately 5.5% of all nasal-type extranodal NK/T-cell lymphoma of both nasal and non-nasal sites. None of these 9 cases had CNS involvement. All patients died of disease shortly, varying from 1 to 40 weeks. The patients usually showed a good initial response to chemotherapy but commonly relapsed [8, 16, 17]. In contrast to the pattern of dissemination of diffuse large B-cell lymphoma of the testis, regional lymph node involvement is quite uncommon in primary testicular NK/T cell lymphoma, even with widely disseminated disease [18].

In the literature review of nasal-type NK/T-cell lymphoma with testicular involvement (Table 1), there are 19 cases of primary testicular lymphoma (including the present case) and 15 cases of testicular involvement as secondary lymphoma. Only one case report by Güler et al. [20] had a presumptive diagnosis of abscess or malignancy. We regarded a 55-year-old patient reported by Chan et al. [18] as primary testicular lymphoma, in contrast to the literature review by Liang et al. [27] that placed him as non-primary testicular case, because this particular case presented first with left testicular mass then 1 month after orchiectomy he developed cutaneous involvement without bone marrow or cerebrospinal fluid involvement. After initiation of combination chemotherapy, nasopharyngeal examination revealed lymphomatous involvement. We also included the two cases of primary testicular lymphoma reported by Lin et al. [9] in this literature review. The comparison between the primary testicular and secondary testicular groups is shown in Table 2. The median age of patients with primary testicular NK/T-cell lymphoma was not different from that of patients with secondary lymphoma (53.5 vs. 47, $p = 0.899$) while the mean age of the former is only 1.6 years older than the latter (50.5 vs. 48.9). The primary testicular NK/T-cell lymphoma group seems to behave less aggressively than the secondary testicular lymphoma group but there is not statistically significant difference in either overall median survival (32 vs. 16 weeks, $p = 0.086$) or mean survival (29.4 vs. 17.9 weeks, $p = 0.083$). In some cases of primary testicular NK/T-cell lymphoma reported in the literature, the disease progressed very rapidly. Involvement of other sites was documented within a month after orchiectomy. It may be

Table 1. Summary of 34 cases of nasal-type NK/T-cell lymphoma involving testis in the literature including the present case

Authors	Age/Race	Angio-centricity	CGAP	CD56	Other IHC+	EBER	TCR	Other Positive Organs	Stage/ Size (max)	Treatment	Res-ponse	Clinical Course after treatment	Survival
Primary testicular NK/T-cell lymphoma, nasal type (19 cases)													
1) Sun et al., 1993 [19]	32/NA	-	NA	+	-	NA	-	-	IA(Rt)/ 3 cm.	Orchiectomy + IFRT + CMT1 + intrathecal MTX	Yes	Relapse 5 mos later with leukemic phase (blood, BM, Spl, Li) & massive GI bleeding	DOD, 6 mos
2) Chan et al., 1996 [18]	71/ NA (Chinese)	-	NA	+	CD3, CD8	+	NA	-	IE(Lt)/ NA	Orchiectomy	No	1 mo later with GI bleeding from ML at jejunum & ileum	DOD, 5 wks (after orchiecto-my)
3) Chan et al., 1996 [18]	55/ NA (Chinese)	+	NA	+	CD3, CD8	+	NA	-	IEB (Lt)/ NA	Orchiectomy	Yes	1 mo later with skin involvement, naso+ even after CMT1; fever, pancytopenia, ascites, peritonitis, DIC	DOD, 5 mos
4) Güler et al., 1999 [20]	35/NA (Turkish)	+ (focal)	NA	+	CD45RO	+	NA	-	IEA (Rt)/ NA	CHOP + radiotherapy	Yes	Relapse 6 mos later, skin, contralateral testis, axillary LN, spleen	Loss to F/U (alive for 14 mos)
5) Pérez-Vallés et al., 2000 [21]	47/NA (Spanish)	+	+	-	CD3 CD45RO	+	+	-	IE (Lt)/ 10 cm.	Orchiectomy + CHOP	Yes	Relapse 2 mos later, skin, fever, pancytopenia, dissemination at autopsy (CNS-)	DOD, 12 mos
6) Totonchi et al., 2002 [22]	66/Korean	+	+	+	CD3ε	+	-	-	IE (Rt)/ 3 cm.	Orchiectomy	NA	NA	NA
7) Kim et al., 2003 [13]	52/Korean	+	+	+	CD3	+	NA	-	IEA (Rt)/4 cm.	Orchiectomy + IFRT + CHOPx3	No	Skin & subcutaneous nodules during IFRT; 1 mo later with leptomeningeal involvement	DOD, 8 mos

8) Ko et al., 2004 [17]	NA/Korean	NA	+	+	NA	+	-	NA	NA/NA	NA	NA	NA	DOD, 10 mos
9) Ng et al., 2004 [16]	61/Malay	NA	+	-	CD3	+	+	-	NA	NA	NA	NA	16 wks
10) Ballereau et al., 2005 [14]	30/French Caucasian	+	NA	+	CD3ε, CD43	+	-	-	IEB (both testes)/ 6.4 cm.	Rt orchiectomy + CMT3	No	Contralateral testis, encephalitis; multiorgan failure	DOD, 2 mos
11) Zeng et al., 2007 [23]	29/NA (Chinese)	+ (promi-nent)	NA	+	CD3 CD45RO	NA (PCR +)	-	-	IEB (Lt)/8 cm.	Orchiectomy + CHOP	NA	Spl, Li, contralateral testis, pancytopenia, peritonitis, DIC	DOD, 2 mos
12) Ornstein et al., 2008 [24]	36/Columbian	+	+	+	CD3	+	+	-	IEB (Lt)/ 7.5 cm.	Orchiectomy + CMT4	No	Relapse within weeks, nasopharynx; radiotherapy + ASCT	Alive (for 9 mos of F/U)
13) Matsuda et al., 2009 [25]	76/Japanese	NA	+	+	CD2, CD3ε, CD43, CD45RO	-	-	-	IEA (Lt)/N A	Orchidectomy+ contralateral orchidectomy + CMT5 + CNS prophylaxis	Yes	Complete remission more than 1 year after conventional therapy alone	Alive (for more than 1 year)
14) Ayadi et al., 2010 [26]	28/Tunisian	+	+	+	CD3, CD8, CD43	+	-	-	IEA/ NA	CHOP (palliative CMT & IFRT on relapse)	No	Relapse 2 mos later, contralateral testis, iliac & subclavicular lymph nodes	DOD, 8 mos
15) Lin et al., 2010 [9]	58/Chinese	NA	+	+	CD3	+	N A	-	IEA (both testes)/ NA	Bilateral orchiectomy	NA	NA	Lost to F/U after D/C
16) Lin et al., 2010 [9]	41/Chinese	NA	+	+	CD3	+	N A	-	IEA (Rt)/ 10 cm.	Orchiectomy	No	Disseminated disease	DOD, 4mos
17) Liang et al., 2011 [27]	61/Chinese	+	+	+	CD3ε	+	N A	-	IEA (Rt)/ 3 cm.	Orchiectomy + CHOP	Yes	Relapse, contralateral testis	Alive with relapse, 13 mos
18) Liang et al., 2011 [27]	68/Chinese	+	-	+	CD3ε	+	-	-	IEA (Lt)/ 6.5 cm.	Orchiectomy + radiotherapy	NA	NA	NA
19) The present case	61/Thai	+	+	+	CD3	+	-	-	IEB (Rt)/ 15 cm.	CHOP + intrathecal methotrexate	Partia l	Progression, 5 mos after Dx, Lt testicular mass & CNS	DOD, 9 mos

Nasal-type NK/T-cell lymphoma involving testis (secondary lymphoma or systemic lymphoma involving testis at presentation) (15 cases)													
1) Chan et al., 1996 [18]	47/ NA (Chinese)	+	NA	+	CD3	+	NA	Nose	IIIEB (Lt)/NA	Orchiectomy + IFRT + CMT2	Yes	Relapse 5 wks later, GI bleeding, nasal obstruction, eye swelling, generalized LN & contralateral testis	DOD, 4 mos
2) Chan et al., 1997 [8]	48/ NA (Chinese)	NA	NA	NA	NA	+	NA	Soft, Pan, Naso, Palate	IV	CMT (M-BACOP)	NA	NA	DOD, 7 wks
3) Chan et al., 1997 [8]	64/ NA (Chinese)	NA	NA	NA	NA	+	NA	Sal, Ton, GI	IV	CMT (mBACOD)	NA	NA	DOD, 5 mos
4) Wright et al., 1998 [7]	22/South African	+	NA	+	CD3	NA	NA	Nasal (4 mos earlier), retroperitoneal mass	IV (Rt)/10 cm.	CMT for nasal NK/T-cell lymphoma + radiotherapy	Yes	Relapse 4 mos later, Rt testicular & retroperitoneal mass	NA
5) Bartolomé et al., 2000 [15]	70/NA	NA	NA	+	CD3	+	NA	Para-aortic LN	II (Lt)/	Orchiectomy + CHOP	Yes	Relapse 4 mos later, retroperitoneal LN & skin	DOD, 5 mos
6) Bartolomé et al., 2000	49/NA	NA	NA	+	CD3	+	NA	Skin	III (Lt)	Orchiectomy + CMT1	Yes	Relapse 2 mos later, peritonitis &	DOD, 3 mos
[15]												intracranial bleeding	
7) Kurpis et al., 2002 [28]	44/NA	+	NA	+	NA	+	NA	Skin	II (both testes)	NA	NA	NA	NA
8) Ng et al., 2004 [16]	75/Chinese	NA	+	+	CD3, CD8	+	-	Skin	NA	NA	NA	NA	35 wks
9) Ng et al., 2004 [16]	69/Chinese	NA	+	+	CD3	+	-	Soft	NA	NA	NA	NA	7 wks
10) Morelli et al., 2007 [29]	81/NA (Italian)	+	NA	+	CD2, CD3, CD7, BCL2	+	NA	Soft, skin, Lt lung	IVA (Lt)/ 110 g.	Bilateral orchiectomy	NA	Died after orchiectomy for surgical complication	DOD, 25 days
11) Liang et al., 2011 [27]	40/Chinese	+	+	+	CD3ε, CD45RO	+	NA	Nasal, BM	IVB (Lt)/ 8 cm.	Orchiectomy + CHOP + radiotherapy	NA	NA	DOD, 11 mos

12) Liang et al., 2011 [27]	44/Chinese	+	+	+	CD3ε	+	-	Adrenal	IVB (both)/ Lt 4 cm., Rt 3 cm.	Orchiectomy + CHOP	NA	NA	DOD, 6 mos
13) Liang et al., 2011 [27]	45/Chinese	+	+	+	CD3ε, CD45RO	+	N A	Nasal	IVA (Lt)/ 3 cm.	Orchiectomy + radiotherapy	NA	NA	NA
14) Liang et al., 2011 [27]	13/Chinese	+	+	+	CD3ε, CD45RO	+	N A	Nasal, LN	IVB (Rt)/ 3 cm.	Orchiectomy + radiotherapy	NA	NA	NA
15) Liang et al., 2011 [27]	22/Chinese	+	+	+	CD3ε	+	-	Nasal, LN	IVB (Rt)/ 4 cm.	Orchiectomy + CHOP + radiotherapy	NA	NA	Alive with disease, 2 mos

ASCT: Allogeneic stem cell transplantation, BM: Bone marrow, CGAP: cytotoxic granule-associated protein, D/C: discharge, DOD: dead of disease, F/U: follow-up, IFRT: involved-field radiation therapy, Li: Liver, LN: Lymph node, mo: month; mos: months, MTX: methotrexate, NA: not available, Pan: Pancreas, Sal: Salivary gland, Soft: Soft tissue, Spl: Spleen, TCR: T-cell receptor, gamma, wks: weeks

CHOP: cyclophosphamide, doxorubicin, vincristine, prednisone

CMT1: Cytoxan, adriamycin, VP-16, methotrexate with leucovorin rescue, ara C, bleomycin, vincristine, and prednisolone (ProMACE-CytaBOM)

CMT2: (MECOP-B)

CMT3: doxorubicine, cyclophosphamide, vindesine, bleomycine, methotrexate

CMT4: cyclophosphamide, vincristine, adriamycin, and dexamethasone (hyper-CVAD) with high-dose cytarabine and methotrexate

CMT5: pirarubicin, cyclophosphamide, vincristine

CNS prophylaxis with methotrexate, cytarabine, and prednisolone

Encephalitis – not proven to be CNS involvement in detail by the authors

Cytoplasmic CD3

Table 2 Comparison of primary and secondary testicular NK/T-cell lymphoma, nasal type, in the literature

Features	Primary (19 cases)a	Secondary (15 cases)	p value
Age (years)			
Range	28-78	13-81	
Median	53.5	47	0-899a
Mean	50.5	48.9	
Side			0.669b
Right	7	3	
Left	7	5	
Both	2	2	
Unilateral	2	-	
Not available	1	5	
Response to treatment			0.237b
Complete remission without relapse	1	-	
Partial remission	-		
No remission	6	1	
Relapse	4	4	
Not available	8	10	
Survival (available in no. cases/total cases)	16/19	11/15	
Range	5-56 weeks	4-44 weeks	
Median	32 weeks	16 weeks	0.866a
Mean	29.4 weeks	17.9 weeks	0.833c

[a] Including the present case

Statistic analysis used: a, Mann-Whitney; b, Fisher's Exact test; c, T-test

arguable that this is in fact patients with progressive disease, already disseminated at the beginning [18]. A case reported by Sun et al. as aggressive NK-cell lymphoma/leukemia [19] initially presented as primary testicular lymphoma but the disease relapsed 5 months after treatment as leukemic phase. In this particular case, azurophilic granules were described in the lymphoma cells but neither immunostaining for cytotoxic granule associated protein nor in situ hybridization for EBER was performed. Nevertheless, this particular case was often included in the literature review as the first case report of nasal-type NK/T-cell lymphoma of the testis.

In general, the recommended treatment for primary testicular lymphoma of any subtypes includes surgery (orchiectomy) together with local radiotherapy, especially involved field radiotherapy, including the involved scrotum, ipsilateral pelvic area, and/or paraaortic area, and six cycles of anthracycline-based chemotherapy [3]. Prophylactic radiation to the contralateral testis [11] and prophylactic intrathecal chemotherapy [5] are also recommended. The only case of primary testicular NK/T-cell lymphoma reported by Matsuda et al. [25] was alive more than 1 year at the time of report after a radical orchiectomy plus prophylactic orchiectomy,

combination chemotherapy and CNS prophylaxis. Nevertheless, it is difficult to determine whether such an extensive management is appropriate and beneficial to the patient. Among the 5 patients of primary testicular NK/T-cell lymphoma with contralateral testicular relapse [14, 20, 23, 26, 27], all of them received combination chemotherapy but four of them did not receive radiotherapy after orchiectomy while only one patient received radiotherapy. In 15 cases of secondary testicular NK/T-cell lymphoma, only one case received both chemotherapy and radiotherapy but still had contralateral testicular involvement later [18]. It is conceivable that prophylactic radiation to the contralateral testis in patient with primary testicular lymphoma might prevent lymphomatous involvement. In the present case, the progression free survival was 2.5 months (77 days) and the overall survival was 9 months after diagnosis. Certainly, the clinical response to systemic chemotherapy may have been compromised as the tumor burden was not reduced as the patient refused both orchiectomy and local radiotherapy.

Relapse has been reported up to 40% of patients with stage I or II disease of primary nasal NK/T-cell lymphoma who received only local irradiation. Lymphomatous involvement at distant sites such as the skin, gastrointestinal tract and testis is quite common, suggesting occult dissemination in these sites but unable to detect by conventional clinical staging procedure [30]. It is possible that patient who presents with testicular or other primary non-nasal NK/T-cell lymphoma should undergo a thorough ENT examination and even PET/CT scan to search for any occult nasal NK/T-cell lymphoma. If nasal involvement is documented, the patient should receive treatment as advanced disease. The use of L-asparaginase in recent regimens of combination chemotherapy has resulted in substantial improvements in outcome in high-risk, refractory or relapsed patients. High-dose chemotherapy and hematopoietic stem-cell transplantation with autologous or allogeneic hematopoietic stem cells may be beneficial to selected patients. Prognostication of patients with clinical prognostic models, such as modified NK prognostic model, and circulating Epstein-Barr DNA load may be useful in the stratification of patients for various treatment modalities [30].

CONFLICT OF INTEREST

The authors declare that they have no conflict of interest.

ACKNOWLEDGMENTS

All three authors, Drs. Sanya Sukpanichnant, Yingyong Chinthammitr, and Naravat Poungvarin, are supported by “Chalermphrakiat” Grant, Faculty of Medicine Siriraj Hospital, Mahidol University.

REFERENCES

1. Sukpanichnant S. Analysis of 1983 cases of malignant lymphoma in Thailand according to the World Health Organization classification. Hum Pathol 2004;35:224-30.
2. Pongpruttipan T, Sukpanichnant S, Assanasen T, et al. Extranodal NK/T-cell lymphoma, nasal type, includes cases of natural killer cell and αβ, γδ, and αβ/γδ T-cell origin: a comprehensive clinicopathologic and phenotypic study. Am J Surg Pathol 2012;36:481-499.
3. Park B-B, Kim JG, Sohn SK, Kang HJ, Lee SS, Eom HS, et al. Consideration of aggressive therapeutic strategies for primary testicular lymphoma. Am J Hematol 2007;82:840-5.
4. Zucca E, Conconi A, Mughal TI, Sarris AH, Seymour JF, Vitolo U, et al. Patterns of outcome and prognostic factors in primary large-cell lymphoma of the testis in a survey by the

International Extranodal Lymphoma Study Group. J Clin Oncol 2003;21:20–7.

5. Touroutoglou N, Dimopoulos MA, Younes A, Hess M, Pugh W, Cox J, et al. Testicular lymphoma: Late relapses and poor outcome despite doxorubicin-based therapy. J Clin Oncol 1995;13:1361-7.
6. Swerdlow HS, Campo E, Harris NL, Jaffe ES, Pileri SA, Stien H, et al. World Health Organization Classification of Tumours. Pathology and Genetics of Tumours of Haematopoietic and Lymphoid Tissues. Lyon: IARC Press; 2008.
7. Wright C, Cooper K, Geiman G, Davidge-Pitts M. Natural killer cell lymphoma in cytology: breaking all the rules – a case report. Diagn Cytopathol 1998;19:9-11.
8. Chan JKC, Sin VC, Wong KF, Ng CS, Tsang WYW, Chan CH, et al. Nonnasal lymphoma expressing the natural killer cell marker CD56: a clinicopathologic study of 49 cases of an uncommon aggressive neoplasm. Blood 1997;89:4501-3.
9. Lin X, Li D, Xie P, Mi C, Lin Q. Primary testicular NK/T-cell lymphoma: a study of two cases and review of literature. Chin J Cancer Res 2010;22:239-44.
10. Ferry JA, Harris NL, Young RH, Coen J, Zietman A, Scully RE. Malignant lymphoma of the testis, epididymis, and spermatic cord. A clinicopathologic study of 69 cases with immunophenotypic analysis. Am J Surg Pathol 1994;18:376–90.
11. Martenson JA Jr, Buskirk SJ, Ilstrup DM, Banks PM, Evans RG, Colgan JP, et al. Patterns of failure in primary testicular non-Hodgkin's lymphoma. J Clin Oncol 1988;6:297–302.
12. Spears W, Morphis J II, Lester S, Williams SD, Einhorn LH. Brain metastases and testicular tumors: Long-term survival. Int J Radiat Oncol Biol Phys 1991;22:17–22.
13. Kim YB, Chang SK, Yang W-I, Hahn JS, Koom WS, Shim SJ, et al. Primary NK/T cell lymphoma of the testis. A case report and review of the literature. Acta Haematol 2003;109:95–100.
14. Ballereau C, Leroy X, Morschhauser F, Fantoni J-C, Lemaitre L, Villers A, et al. Testicular natural killer T-cell lymphoma. Int J Urol 2005;12:223-4.
15. Bartolomé J, González-Arenas M, Menarguez J, Gil J. Nasal type T/NK cell lymphoma with testicular presentation. [Letter] Med Clin (Barc) 2000;114:318. [Spanish]
16. Ng SB, Lai KW, Murugaya S, Lee KM, Loong SL, Fook-Chong S, et al. Nasal-type extranodal natural killer/T-cell lymphomas: a clinicopathologic and genotypic study of 42 cases in Singapore. Mod Pathol 2004;17:1097-107.
17. Ko YH, Cho E-Y, Kim J-E, Lee S-S, Huh J-R, Chang H-K, et al. NK and NK-like T-cell lymphoma in extranasal sites: a comparative clinicopathological study according to site and EBV status. Histopathology 2004;44:480-9.
18. Chan JKC, Tsang WYW, Lau WH, Cheung MMC, Ng WF, Yuen WC, et al. Aggressive T/natural killer cell lymphoma presenting as testicular tumor. Cancer 1996;77:1198-205.
19. Sun T, Brody J, Susin M, Marino J, Teichberg S, Koduru P, et al. Aggressive natural killer cell lymphoma/leukemia. A recently recognized clinicopathologic entity. Am J Surg Pathol 1993;17:1289-99.
20. Güler G, Altinock G, Üner AH, Sungur A. CD56+ lymphoma presenting as a testicular tumor. Leuk Lymphoma 1999;36:207-11.
21. Pérez-Vallés A, Sabater-Marco V, Carpio-Máñez D, Botella-Estrada R, Nogueira-Vázquez E, Martorell-Cebollada M. Extranodal

peripheral T-cell lymphoma with angiocentric growth pattern and Epstein-Barr viral DNA associated affecting paratesticular soft tissue. J Cutan Pathol 2000;27:80-6.

22. Totonchi KF, Engel G, Weisenberg E, Rhone DP, Macon WR. Testicular Natural Killer/T-Cell Lymphoma, Nasal Type, of True Natural Killer–Cell Origin. Arch Pathol Lab Med 2002;126:1527-9.
23. Zeng QB, Cheng FJ, Gao QP, Zhu ZP, Liu QH, Yu Q, et al. Primary NK/T-cell lymphoma of the testis: a case report and review of the literature [J]. Chin-Germ J Clin Oncol 2007;6:596−600.
24. Ornstein DL, Bifulco CB, Braddock DT, Howe JG. Histopathologic and molecular aspects of CD56+ natural killer/T-cell lymphoma of the testis. Int J Surg Pathol 2008;16:291-300.
25. Matsuda M, Iwanaga T, Hashimoto S, Uesugi T, Itagaki N. Primary Epstein-Barr virus-negative nasal-type natural killer.T cell lymphoma of the testis. [Letter to the Editor] Leukemia Research 2009;33:e119-e120. – change to ref.19
26. Ayadi L, Makni S, Toumi N, Hammami S, Charfi S, Frikha M, et al. Aggressive nasal-type natural killer/T-cell lymphoma associated with Epstein Barr virus presenting as testicular tumor. Tunis Med 2010 Mar;88(3):196-8.
27. Liang DN, Yang ZR, Wang WY, et al. Extranodal nasal type natural killer/T-cell lymphoma of testis: report of seven cases with review of literature. Leuk Lymphoma 2012 Jan 3. [Epub ahead of print]
28. Kurpis M, Diller A, Calafat P, Ruiz Lascano A. Extranodal NK/T cell lymphoma of the nasal type. Rev Fac Cien Med Univ Nac Cordoba 2002;59:117-20. [Spanish]
29. Morelli L, Piscioli I, Licci S, Del Nonno F, Neri M, Sabattini E. T/natural killer-cell lymphoma of the testis with cutaneous and subcutaneous soft tissue involvement: a management problem. [Letter to the editor] Ann Hematol 2007;6:469-70.
30. Kwong Y-L. Hematopoietic stem cell transplantation in natural killer cell lymphoma and leukemia. Int J Hematol (2010) 92:702-7.