ASIAN ARCHIVES OF PATHOLOGY

THE OFFICIAL JOURNAL OF THE ROYAL COLLEGE OF PATHOLOGISTS OF THAILAND

Volume 3
Number 4
October – December 2021

INDEX COPERNICUS INTERNATIONAL

Print ISSN: 1905-9183

Online ISSN: 2673-0499

EDITORIAL BOARD

ABOUT THE JOURNAL

Aims and Scope

Asian Archives of Pathology (AAP) is an open access, peer-reviewed journal. The journal was first published in 2002 under the Thai name "วารสารราชวิทยาลัยพยาธิแพทย์แห่งประเทศไทย" and English name "Journal of the Royal College of Pathologists of Thailand". The journal is a publication for workers in all disciplines of pathology and forensic medicine. In the first 3 years (volumes), the journal was published every 4 months. Until 2005, the journal has changed its name to be "Asian Archives of Pathology: The Official Journal of the Royal College of Pathologists of Thailand", published quarterly to expand the collaboration among people in the fields of pathology and forensic medicine in the Asia-Pacific regions and the Western countries.

The full articles of the journal are appeared in either Thai or English. However, the abstracts of all Thai articles are published in both Thai and English languages. The journal features letters to the editor, original articles, review articles, case reports, case illustrations, and technical notes. Diagnostic and research areas covered consist of (1) **Anatomical Pathology** (including cellular pathology, cytopathology, haematopathology, histopathology, immunopathology, and surgical pathology); (2) **Clinical Pathology (Laboratory Medicine)** [including blood banking and transfusion medicine, clinical chemistry (chemical pathology or clinical biochemistry), clinical immunology, clinical microbiology, clinical toxicology, cytogenetics, parasitology, and point-of-care testing]; (3) **Forensic Medicine (Legal Medicine or Medical Jurisprudence)** (including forensic science and forensic pathology); (4) **Molecular Medicine** (including molecular genetics, molecular oncology, and molecular pathology); (5) **Pathobiology**; and (6) **Pathophysiology**.

All issues of our journal have been printed in hard copy since the beginning. Around the late 2014, we developed our website (www.asianarchpath.com) in order to increase our visibility. We would like to acknowledge that our journal has been sponsored by the Royal College of Pathologists of Thailand. We have the policy to disseminate the verified scientific knowledge to the public on a non-profit basis. Hence, we have not charged the authors whose manuscripts have been submitted or accepted for publication in our journal.

On the other hand, if any authors request a printed copy of the journal issue containing the articles, each of the copied journals costs 450 bahts for Thai authors and 30 United States dollars (USD) for international authors.

Publication Frequency

Four issues per year

Disclaimer

The Royal College of Pathologists of Thailand and Editorial Board cannot be held responsible for errors or any consequences arising from the use of information contained in Asian Archives of Pathology. It should also be noted that the views and opinions expressed in this journal do not necessarily reflect those of The Royal College of Pathologists of Thailand and Editorial Board.

MANUSCRIPT REVIEWERS

CONTENTS

LETTER TO THE EDITOR

ระดับของโปรตีนเอ็มเอ็มพี-1 โปรตีนเอ็มเอ็มพี-9 และโปรตีนทีไอเอ็มพี-1 ในบาดแผลเรื้อรังที่เท้าจากภาวะเบาหวาน

(The levels of MMP-1, MMP-9 and TIMP-1 proteins in chronic diabetic foot ulcer)

ภัสรา อาณัติ

ภาควิชาชีวเคมี ชั้น 5 อาคารเจ้าฟ้าเพชรรัตน วิทยาลัยแพทยศาสตร์พระมงกุฎเกล้า
เลขที่ 317 ถนนราชวิถี แขวงทุ่งพญาไท เขตราชเทวี จังหวัดกรุงเทพมหานคร รหัสไปรษณีย์ 10400
โทรศัพท์: +66 (0) 83 619 8689 Email: pasra@pcm.ac.th, pasra@hotmail.com

ผลประโยชน์ทับซ้อน: ผู้นิพนธ์แจ้งให้ทราบโดยทั่วกันว่าไม่มีผลประโยชน์ทับซ้อนในเนื้อหาของบทความนี้

ส่งต้นฉบับ: วันที่ 23 เดือนมีนาคม พ.ศ. 2564
รับลงตีพิมพ์: วันที่ 6 เดือนเมษายน พ.ศ. 2564
ตีพิมพ์เผยแพร่: วันที่ 1 เดือนตุลาคม พ.ศ. 2564

เบาหวาน (Diabetic mellitus) เป็นโรคเรื้อรังทางสาธารณสุขที่สำคัญโรคหนึ่งในปัจจุบัน โดยภาวะแทรกซ้อนที่พบบ่อยของโรคนี้คือการเกิดแผลเบาหวานที่เท้า (Diabetic foot ulcer) สามารถพบได้ถึงร้อยละ 15 ของผู้ป่วยเบาหวาน และคิดเป็นร้อยละ 84 ของผู้ป่วยเบาหวานที่ต้องได้รับการตัดขา[1,2] สาเหตุการเกิดแผลเบาหวานเรื้อรังจากโรคเบาหวานคือ การสูญเสียสภาพ (Impairment) ของหลอดเลือดแดงขนาดใหญ่ (Macrocirculation) หลอดเลือดแดงขนาดเล็ก (Microcirculation) และระบบเส้นประสาทรับความรู้สึก (Sensory nerve) ทั้งนี้การสมานบาดแผล (Wound healing) ในภาวะปกติของร่างกายจะมีการสร้างเอ็นไซม์ Matrix metalloproteinases (MMPs) ซึ่งเป็นกลุ่มของเอ็นไซม์ที่สร้างจากเซลล์หลายชนิด และมีบทบาทในกระบวนการจัดโครงร่างเนื้อเยื่อโดยเปลี่ยนแปลงสภาวะรอบนอกเซลล์ด้วยการย่อยสารประกอบโปรตีนนอกเซลล์ (Extracellular matrix)

โปรตีน MMPs แบ่งเป็นหลายชนิดขึ้นอยู่กับสารตั้งต้นที่จำเพาะกับเอ็นไซม์ชนิดนั้น ๆ จากการศึกษาก่อนหน้านี้พบว่าโปรตีน MMP-1 และโปรตีน MMP-9 มีบทบาทสำคัญต่อการสมานบาดแผลเรื้อรังในผู้ป่วยเบาหวาน ทั้งนี้ระดับของโปรตีน MMP-1 ที่สูงขึ้นจะช่วยในการสมานบาดแผล ขณะที่ระดับของโปรตีน MMP-9 ที่มากเกินไปจะทำให้เกิดอันตรายต่อกระบวนการสมานบาดแผล โดยทำให้กระบวนการสร้างเนื้อเยื่อใหม่ไม่เป็นไปตามปกติ นอกจากนี้โปรตีน Tissue inhibitor of metalloproteinase-1 (TIMP-1) จะทำหน้าที่ยับยั้งการทำงานของโปรตีน MMP-1 และโปรตีน MMP-9 จึงเป็นกลไกที่ควบคุมความสมดุลของกระบวนการสมานบาดแผล[3,4] และยังมีการศึกษาพบว่าโปรตีน MMP-1 และโปรตีน MMP-9 มีบทบาทสำคัญต่อการหายของแผลเรื้อรังในผู้ป่วยเบาหวาน โดยอัตราส่วนระหว่างโปรตีน MMP-1 กับโปรตีน TIMP-1 ที่เพิ่มสูงขึ้นมีความสัมพันธ์กับการหายของบาดแผลที่ดีขึ้น[5] แม้กระนั้นก็ตามอัตราส่วนระหว่างโปรตีน MMP-9 กับโปรตีน TIMP-1 ในน้ำเหลืองเลือด (Serum MMP-9/TIMP-1) ที่มากเกินไปมีความสัมพันธ์ในการทำนายการหายของบาดแผลที่ช้าลง[6]

เอกสารอ้างอิง

(1). American Diabetes Association. Diagnosis and classification of diabetes mellitus. Diabetes care 2004; 27(1): 5-10.

(2). Stanley S, Turner L. A collaborative care approach to complex diabetic foot ulceration. Br J Nurs. 2004; 13(13): 788-93.

(3). Rayment EA, Upton Z, Shooter GK. Increased matrix metalloproteinase-9 (MMP-9) activity observed in chronic wound fluid is related to the clinical severity of the ulcer. Br J Dermatol. 2008;158(5): 951-61.

(4). Trengove NJ, Stacey MC, MacAuley S, et al. Analysis of the acute and chronic wound environments: the role of proteases and their inhibitors. Wound Repair Regen. 1999; 7(6): 442-52.

(5). Muller M, Trocme C, Lardy B, Morel F, Halimi S, Benhamou PY. Matrix metalloproteinases and diabetic foot ulcers: the ratio of MMP-1 to TIMP-1 is a predictor of wound healing. Diabet Med 2008; 25(4): 419-26.

(6). Li Z, Guo S, Yao F, Zhang Y, Li T. Increased ratio of serum matrix metalloproteinase-9 against TIMP-1 predicts poor wound healing in diabetic foot ulcers. J Diabetes Complications. 2013; 27(4): 380-2.

ORIGINAL ARTICLE

Comparison between unbuffered and buffered formalin fixatives for oestrogen receptor and Ki67 immunostains in breast cancer specimens: a pilot study

Chetsada Chunkaruhart[1], Nopporn Tipparawong[2] and Kroonpong Iampenkhae[2*]

1 *Department of Pathology, Faculty of Medicine, Chulalongkorn University, Bangkok, Thailand*

2 *Department of Pathology, King Chulalongkorn Memorial Hospital, Bangkok, Thailand*

* Correspondence to: Dr Kroonpong Iampenkhae, Department of Pathology, Floor 13, His Majesty King Ananda Mahidol Building, 1873 King Chulalongkorn Memorial Hospital, Rama IV Road, Pathumwan, Bangkok 10330 Thailand. Telephone: +66 (0) 2 256 4235, +66 (0) 2 256 4581 Facsimile: +66 (0) 2 652 4208 Email: kroonpong@gmail.com

Conflict of interest: The authors declare that they have no conflicts of interest with the contents of this article.

Submitted: *12 April 2021*
Accepted: *21 April 2021*
Published: *1 October 2021*

Abstract

Pre-analytic steps are important for the immunohistochemical study as in the case of breast cancers. The initial process is the fixation in which the 10% neutral buffered formalin (NBF) is recommended. 10% formalin is less expensive and easier to prepare but its effect on the immunostaining is controversial. The aim of this study was to compare the effect of 10% formalin with 10% NBF on oestrogen receptor (ER) and Ki67 immunostains in breast cancer specimens. Thirty breast cancer specimens were collected. Each tumour was bisected and separately fixed in 10% formalin and 10% NBF, processed, and immunostained with ER and Ki67. Whole slides were scanned and evaluated by digital image analysis. A semiquantitative H-score was determined. No significant differences, both the percentage and H-score, of the ER- and Ki67-positive cells were found between breast cancer specimens fixed in 10% formalin and 10% NBF. In conclusion, 10% formalin could be used as a fixative for immunohistochemical study for breast biomarkers. The unbuffered fixative is less expensive and easier to prepare, compared to 10% neutral buffered formalin. Additional study is reasonable to evaluate the effect of 10% formalin to the quality of nucleic acid.

Keywords: 10% formalin; 10% neutral buffered formalin; breast cancers; ER; Ki67

Introduction

Breast cancer is one of the leading cancers in Thailand, with the highest incidence among cancers in women[1-3]. During 2013 – 2015, the age-standardised incidence rate (ASR) of breast cancer was 31.4 per 100,000 in Thai women[1]. Like many other malignancies, breast cancer is not a single disease as it can be categorised into luminal A, luminal B, HER2/Neu-overexpression, and basal-like subtypes[4]. College of American Pathologists (CAP)/American Society of Clinical Oncology (ASCO) guidelines recommend oestrogen receptor (ER), progesterone receptor (PR) and HER2/neu (HER2) analysis for all new diagnoses of breast cancer. In routine practice, all breast cancer specimens in Thailand are subject to immunohistochemical study for evaluation of ER, PR, HER2 and Ki67. These biomarkers have long been used to select an appropriate treatment for an individual patient[4,5]. ER and PR are the prognostic factors and predictive for the benefit with the endocrine treatment[6].

Pre-analytic process is especially important to ensure the good immunohistochemistry result, and fixation is one of the crucial steps. While 10% Neutral buffered formalin (NBF) is recommended[7-9], some laboratories in Thailand — a middle-income country — still use 10% formalin as it is much less expensive. In addition, 10% formalin is easily prepared by only adding nine parts of water, preferably distilled, to one part of the stock formalin. This is in contrast with the preparation of 10% NBF that needs buffer, typically sodium phosphate, to adjust the pH[10].

Although 10% formalin and 10% NBF have been compared as fixatives; for example, Arima et al. found Ki67 was significantly higher when 10% NBF was used[11], the Ki67 was scored by manual counting in the hot spots without the use of digital image analysis (DIA). The purpose of our study was to re-evaluate the effect of 10% formalin on breast cancer biomarkers, using ER and Ki67 as a model, and compare the results with those obtained from 10% NBF fixative. DIA was used for the objective scoring. This study was approved by the Institutional Review Board at the Faculty of Medicine, Chulalongkorn University (IRB # 132/64).

Materials and Methods

Fixatives:

10% formalin was prepared weekly by dissolving 100 mL of commercially available formalin (100% formalin, TOA Dovechem Industries Co.,Ltd., Bangkok, Thailand) in 900 mL of distilled water. 10 % formalin was prepared fresh from stock solutions before use every week. 10% NBF (Bio-Optica Milano S.p.A., Milan, Italy) was purchased in a ready-to-use form. The pH

level of 10% formalin and 10% NBF was 5 and 7, respectively (measured by Litmus paper). All fixatives were precautionarily stored and used at room temperature.

Specimen collection and fixation:

Thirty fresh specimens of the breast cancer were received from the Department of Surgery, King Chulalongkorn Hospital. Cold ischaemia time is less than one hour. For each case, the tumour was cut into two pieces (less than 5 mm in thickness). One half was immediately fixed in 10% formalin, and the other half in 10% NBF for 24 – 48 hours. The 1:15 ratio of tissue volume to formalin volume was used. After fixation, both halves of the tumour were routinely processed and embedded in the same paraffin block.

Immunohistochemistry:

Four-µm-thick sections were deparaffinization and underwent antigen retrieval using EnVision FLEX High pH Target Retrieval Solution for Dako PT LINK tank (Agilent Technologies, California, United States of America). The antibodies used in the study were also from Dako, including a monoclonal rabbit Anti-Human Estrogen Receptor alpha antigen (clone EP1, ready-to-use) and a monoclonal mouse Anti-Human Ki67 antigen (clone MIB-1, ready-to-use). All immunostains were carried out with a Dako Autostainer Link 48.

Image and data analyses:

Whole ER- and Ki67-stained sections were converted into digital format using Aperio CS2 scanner (Aperio Technologies Inc., California, United States of America) using Aperio ImageScope (v12.3.2.5030). The tumour fixed with 10% NBF and 10% formalin in each whole section was selected for annotation. ER- and Ki67-positive nuclei were analysed by Nuclear v9 algorithm (Aperio's Image Analysis Kit) on whole tumour areas. Parameters examined included percentage of positive cells and percentage of different staining intensity (0, 1+, 2+, 3+) (*Figure 1*).

A semiquantitative approach was also performed to assign an H-score [H-score (0-300 scale) = 3 x (% at 3+) + 2 x (% at 2+) + 1 x (% at 1+)]. Results of ER and Ki67 were compared between specimens with different fixatives, using the Mann–Whitney U test (IBM SPSS version 22.0, SPSS Inc., Chicago, IL). The p-value of < 0.05 was considered statistical significance.

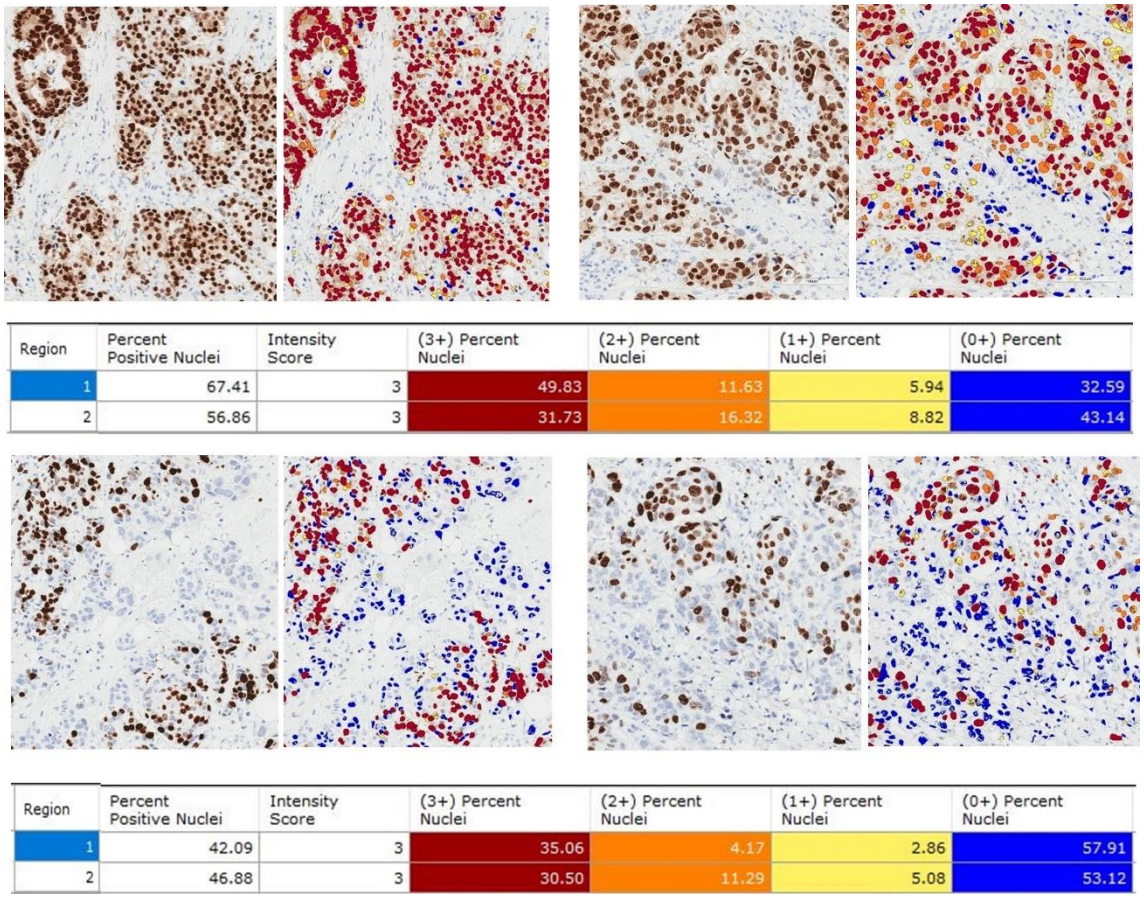

Region	Percent Positive Nuclei	Intensity Score	(3+) Percent Nuclei	(2+) Percent Nuclei	(1+) Percent Nuclei	(0+) Percent Nuclei
1	67.41	3	49.83	11.63	5.94	32.59
2	56.86	3	31.73	16.32	8.82	43.14

Region	Percent Positive Nuclei	Intensity Score	(3+) Percent Nuclei	(2+) Percent Nuclei	(1+) Percent Nuclei	(0+) Percent Nuclei
1	42.09	3	35.06	4.17	2.86	57.91
2	46.88	3	30.50	11.29	5.08	53.12

Figure 1 Example of digital image analysis of ER (*Upper panel*) and Ki67 (*Lower panel*) immunostains in breast cancer tissue, with prior 10% formalin (*Left*) and 10% neutral buffered formalin (*Right*) fixation (Nuclear v9 algorithm, Aperio Image Analysis software).

Results

Of the total 30 cases of female breast cancers enrolled for the study, 29 were invasive ductal carcinoma while the remaining was an invasive lobular carcinoma. The mean age of patients was 57.2 years. The median percentage of ER-positive cells in tissue fixed with 10% formalin (68.18; min – max = 0.49 – 97.62; mean = 52.78) and 10% NBF (65.75; min – max = 0.04 – 98.16; mean = 52.64) was not significantly different (*Figure 2A*) (p = 0.848). Also, the median H-score of ER-positive cells in tissue fixed with 10% formalin (173.55; min – max = 0.70 – 279.75; mean = 131.10) and 10% NBF (143.30; min – max = 0.06 – 275.23; mean = 127.99) did not significantly differ (p = 0.734) (*Figure 2B*).

For the Ki67 staining, the medians of Ki67 index of the tumours fixed in 10% formalin and 10% NBF were 32.94 (min – max = 7.99 – 81.06; mean = 37.29) and 29.45 (min – max =

6.87 – 83.78; mean = 35.39), respectively. The median H-score of ER-positive cells in tissue fixed with 10% formalin was 87.42 (min – max = 21.07 – 210.36; mean = 95.07) whereas that of the tissue fixed with 10% NBF was 75.0 (min – max = 16.25 – 208.38; mean = 89.29). Comparison of both parameters between the different fixatives did not show significant differences (*Figure 3*).

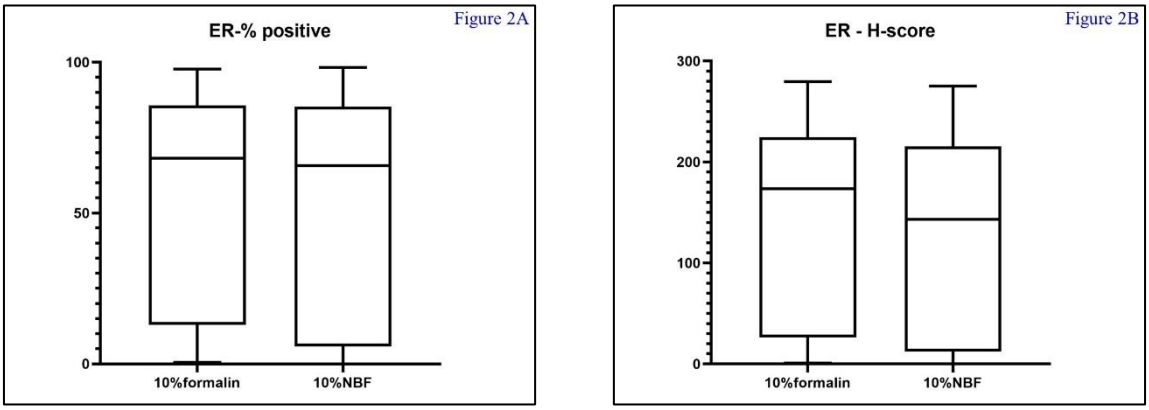

Figure 2 Percentages (A) and H-Score (B) of ER-positive cells. There was no significant difference noted between samples fixed with 10% formalin and 10% neutral buffered formalin (p = 0.848 and 0.734, respectively).

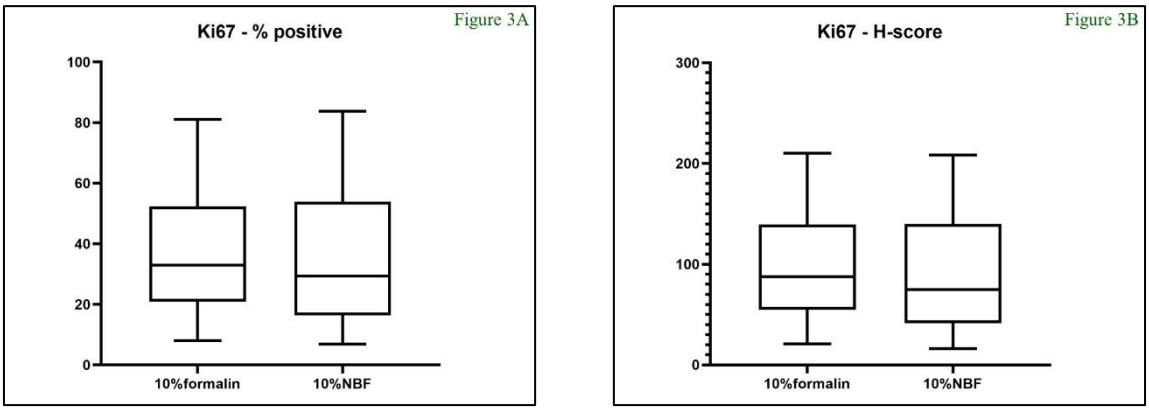

Figure 3 Percentages (A) and H-Score (B) of Ki67-positive cells. There was no significant difference noted between samples fixed with 10% formalin and 10% neutral buffered formalin (p = 0.478 and 0.525, respectively).

Discussion

Evaluation of breast biomarkers is essentially important to select an appropriate treatment for the patients. Although the immunohistochemical method has remarkably been improved, with the use of automated immunostainers, pre-analytic steps such as cold ischaemic time (time to fixation), fixative (solution that prevents autolysis), fixation time (duration of fixation), are still vital to ensure the reliable results. Improper pre-analytic steps can significantly affect treatment decisions[12]. These pre-analytic factors have been studied quite extensively in breast cancer biomarkers[13-19]. The recommended cold ischaemic time and fixation time are as soon as possible (or less than one hour) and 6 – 72 hours, respectively, according to the American Society of Clinical Oncology (ASCO)/College of American Pathologists (CAP) 2020[7,24].

Formalin is a universal fixative in surgical pathology, and the volume of fixative should be sufficient or 20 times the volume of tissue[7,8]. 10% buffered neutral formalin (BNF), pH (7.2 – 7.4), is recommended since both acidity or alkalinity can interfere with the fixation process[7,20]. Compared to 10% NBF (130.80 Bahts/litre), 10% formalin (2.75 Bahts/litre) is much less expensive and easier to prepare but the latter is usually acid (pH = 5.0 to 5.5). Because of the cost and preparation process, 10% formalin is still used in some pathology laboratories. Differences between 10% NBF and 10% formalin on the performance of immunostaining are somewhat controversial. Unbuffered formalin was said to be a better fixative for the immunorecognition of many antigens[21].

Matsuda et al. studied formalin-fixed paraffin-embedded tissue of nude mice implanted with human uterine cervical cancer cells using immunostains and image analysis on limited microscopic fields[22]. Compared to specimens fixed with 10% NBF, Ki-67 stain performed in samples with unbuffered formalin showed slightly higher expression. However, no statistical analysis was conducted in this study. Without image analysis, Burns JA et al. noted slightly higher staining intensities of HER2 in cancer tissue fixed with 10% NBF, compared to those prior fixed with unbuffered formalin although this did not reach the statistical significance[23].

The methods used for counting (manual vs. digital image analysis) may have accounted for the discrepancy. Digital image analysis (DIA) has been shown to be superior alternative to the manual biomarker scoring[24]. Stålhammar et al. demonstrated that the DIA of Ki67 in hot spots was better than manual Ki67 counts in breast cancers[25]. In our study of ER and Ki67 scoring using DIA, we were not able to show significant differences between breast cancer specimens fixed with 10% NBF and 10% formalin.

It should be noted that prolonged storage of unbuffered formalin may induce precipitation of white para-formaldehyde deposits and produce turbidity. Traces of formic acid are formed by oxidation, which decreases the quality of nuclear staining and leaches out haemosiderin resulting in formation of brown-black pigment called formalin pigment[26]. To avoid prolonged storage of formalin, 10% formalin solution should be regularly prepared (e.g., weakly). NBF has a longer shelf life[23] and the tissue fixed with NBF has been shown to have better RNA quality[27,28]. In our study, 10% formalin was freshly prepared every week. 10% NBF was shortly stored too. This is the possible explanation that 10% formalin seemed to be consistently superior to 10% NBF through not statically different.

PR and HER2 stains were not included in our study, further studies of these stains are considered. Whole tumour areas were analysed but more sample sizes may show the difference of the results. The aim of this study is the comparison of preserved antigenicity between unbuffered and buffered formalin, dividing the group of high and low ER and Ki67 expression may not be significant differences between groups. Since the molecular testing is increasingly needed, further studies are warranted to determine the effect of 10% formalin on the quality of nucleic acid.

Conclusion

10% formalin could be used as a fixative for immunohistochemical study for breast biomarkers. The unbuffered fixative is less expensive and easier to prepare, compared to 10% neutral buffered formalin. Additional study is reasonable to evaluate the effect of 10% formalin to the quality of nucleic acid.

References

(1). Imsamran W, Adisia P, Pongsatorn S, et al. Cancer in Thailand. IX., 2013 – 2015 Bangkok:National Cancer Institute 2015:6.

(2). Imsamran W, Chaiwerawattana A, Wiangnon S, et al. Cancer in Thailand. VIII., 2010 – 2012. Bangkok:National Cancer Institute 2015:12.

(3). Khuhaprema T, Attasara P, Sriplung H, et al. Cancer in Thailand. Vol. VII, 2007 – 2009. Bangkok: National Cancer Institute 2013:10.

(4). Goldhirsch A, Winer EP, Coates AS, Gelber RD, Piccart-Gebhart M, Thürlimann B, Senn HJ. Panel members: personalizing the treatment of women with early breast cancer: highlights of the St Gallen International Expert Consensus on the Primary Therapy of Early Breast Cancer. Annals of Oncology 2013;24:2206–2223.

(5). Atif Ali Hashmi et. al. Ki67 index in intrinsic breast cancer subtypes and its association with prognostic parameters. BMC Research Notes 2019;12(1).

(6). Nicolini A, Ferrari P, Duffy MJ. Prognostic and predictive biomarkers in breast cancer: past, present and future. Seminars in Cancer Biology 2018;52(Pt 1):56-73.

(7). Kimberly H. Allison, M. Elizabeth H. Hammond, et al. Estrogen and progesterone receptor testing in breast cancer: ASCO/CAP guideline update. Journal of Clinical Oncology 2020; 38:1346-1366.

(8). Wolff AC, Hammond MEH, Allison KH, er al. Human Epidermal Growth Factor Receptor 2 Testing in Breast Cancer: American Society of Clinical Oncology/College of American Pathologists clinical practice guideline focused update. Archives of Pathology & Laboratory Medicine 2018;142(11):1364-1382.

(9). Nielsen, T. O., Leung, S. C. Y., Rimm, D. L., et. al. Assessment of Ki67 in Breast Cancer: Updated recommendations from the International Ki67 in Breast Cancer Working Group. JNCI: Journal of the National Cancer Institute 2020;djaa201.

(10). Dey, P. Basic and Advanced Laboratory Techniques in Histopathology and Cytology (1st ed. 2018 ed.). Springer. 2018:10-11.

(11). Arima N, Nishimura R, Osako T, et al. The importance of tissue handling of surgically removed breast cancer for an accurate assessment of the Ki-67 index. Journal of Clinical Pathology 2016;69:255–259.

(12). Maung R, Work pattern of Canadian pathologists. Diagnostic Histopathology 2016;22:288–293.

(13). Portier BP, Wang Z, Downs-Kelly E, et al. Delay to formalin fixation 'cold ischemia time': effect on ERBB2 detection by in-situ hybridization and immunohistochemistry. Modern Pathology 2013;26:1–9.

(14). Khoury T, Sait S, Hwang H, et al. Delay to formalin fixation effect on breast biomarkers. Modern Pathology 2009;22:1457–67.

(15). Walker RA. Immunohistochemical markers as predictive tools for breast cancer. Journal of Clinical Pathology 2008;61:689–96.

(16). Hewitt SM, Lewis FA, Cao Y, et al. Tissue handling and specimen preparation in surgical pathology. Archives of Pathology & Laboratory Medicine 2008;132:1929–35.

(17). Goldstein NS, Ferkowicz M, Odish E, et al. Minimum formalin fixation time for consistent estrogen receptor immunohistochemical staining of invasive breast carcinoma. American Journal of Clinical Pathology 2003;120:86–92.

(18). Goldstein NS, Hewitt SM, Taylor CR, et al. Members of Ad-Hoc committee on immunohistochemistry standardization. Recommendations for improved standardization of immunohistochemistry. Applied Immunohistochemistry & Molecular Morphology 2007;15:124–33.

(19). Tong LC, Nelson N, Tsourigiannis J, et al. The effect of prolonged fixation on the immunohistochemical evaluation of estrogen receptor, progesterone receptor, and HER2 expression in invasive breast cancer: a prospective study. The American Journal of Surgical Pathology 2011;35:545–52.

(20). Thavarajah, R., Mudimbaimannar, V. K., Rao, U. K., Ranganathan, K., & Elizabeth, J. Chemical and physical basics of routine formaldehyde fixation. Journal of Oral and Maxillofacial Pathology 2012;16(3):400.

(21). Arnold, M. M., Srivastava, S., Fredenburgh, J., et al. Effects of fixation and tissue processing on immunohistochemical demonstration of specific antigens. Biotechnic and Histochemistry 1996;71:224–230.

(22). Matsuda, Y., Fujii, T., Suzuki, T., Yamahatsu, K., Kawahara, K., Teduka, K., Kawamoto, Y., Yamamoto, T., Ishiwata, T., & Naito, Z. Comparison of fixation methods for preservation of morphology, RNAs, and proteins from paraffin-embedded human cancer cell-implanted mouse models. Journal of Histochemistry & Cytochemistry 2011;59(1): 68–75.

(23). Burns, J. A., Li, Y., Cheney, C. A., Ou, Y., Franlin-Pfeifer, L. L., Kuklin, N., & Zhang, Z.-Q. (2008). Choice of fixative is crucial to successful immunohistochemical detection of phosphoproteins in paraffin-embedded tumor tissues. Journal of Histochemistry & Cytochemistry 2008;57(3):257–264.

(24). Stålhammar, G., Fuentes Martinez, N., Lippert, M., Tobin, N. P., Mølholm, I., Kis, L., Rosin, G., Rantalainen, M., Pedersen, L., Bergh, J., Grunkin, M., & Hartman, J. Digital image analysis outperforms manual biomarker assessment in breast cancer. Modern Pathology 2016.

(25). Stålhammar, G., Robertson, S., Wedlund, L., Lippert, M., Rantalainen, M., Bergh, J., & Hartman, J. Digital image analysis of Ki67 in hot spots is superior to both manual Ki67 and mitotic counts in breast cancer. Histopathology 2018 May;72(6):974-989.

(26). Shariff, S., & Kaler, A. K.. Principles and Interpretation of Laboratory Practices in Surgical Pathology (1st ed.). Jaypee Brothers Medical Publishers Pvt Ltd. 2016:5-7.

(27). Chung, J.-Y., Braunschweig, T., Williams, R., Guerrero, N., Hoffmann, K. M., Kwon, M., Song, Y. K., Libutti, S. K., & Hewitt, S. M. Factors in tissue handling and processing that impact RNA obtained from formalin-fixed, paraffin-embedded tissue. Journal of Histochemistry & Cytochemistry 2008;56(11):1033–1042.

(28). Seo, A. N., Kim, J.-H., Lee, D., Jeong, J. Y., & Park, J.-Y. Comparison of the DNA preservation in neutral-buffered formalin-fixed, paraffin-embedded tissue and in non-buffered formalin-fixed, paraffin-embedded tissue. The Korean Journal of Pathology, 2011;45(6): 549.

CASE REPORT

A case report on primary cutaneous anaplastic large cell lymphoma

Win Myat Oo[1*], Sein Win[2] and Nyein Chan Aung[3]

1 *Department of Pathology, No (1) Defence Services General Hospital, Mingalardon, Yangon, Myanmar*
2 *Department of Clinical Haematology, Yangon General Hospital, Yangon, Myanmar*
3 *Department of Pathology, Defence Service Medical Academy, Yangon, Myanmar*

* Correspondence to: Dr Win Myat Oo, Department of Pathology, No (1) Defence Services General Hospital, Pyay Street, Mingalardon, Yangon 11021 Myanmar. Telephone: +95 940 930 7131 Email: winmo27@gmail.com

Conflict of interest: The authors declare that they have no conflicts of interest with the contents of this article.

Submitted: *24 March 2021*
Accepted: *5 April 2021*
Published: *1 October 2021*

Abstract

Primary cutaneous anaplastic large cell lymphoma (PCALCL) is a rare T-cell lymphoma, characterised by anaplastic large cells that are usually ALK negative but have high expression of CD30 and presents as a solitary or grouped nodules. It is the second most common type of cutaneous T-cell lymphoma, usually skin-limited disease and most frequently affects the trunk, face and extremities. In about 10% of the patients, it involves the regional lymph nodes as extracutaneous dissemination. We presented a 52-year-old male with ulcerated skin tumour mass at dorsal aspect of left hand near the base of little thumb and one regional lymph node enlargement in left bicep muscle. Skin tumour mass showed diffuse lymphomatous infiltrate in the dermal portion containing cohesive sheets of neoplastic medium to large cells mixed with few inflammatory cells and histiocytes. There was no epidermotrophism. Tumour cells were positive for CD3, CD30, MUM1 and high Ki67 expression. Heterogenous expression of CD4 and CD8 were noted. They were negative for CD20, CD5, EMA, TIA1, ALK and EBV/LMP1 expression and it matched with primary cutaneous anaplastic large cell lymphoma. Regional lymph node shows the same morphology and the neoplastic large cells had strong expression of CD3 and CD30.

Keywords: CD30 expression; immunophenotyping of lymphoma; primary cutaneous anaplastic large cell lymphoma; T-cell lymphoma

Introduction

Primary cutaneous anaplastic large cell lymphoma (PCALCL) is a rare T-cell lymphoma, characterised by anaplastic large cells that are usually ALK negative but have high expression of CD30 and presents as a solitary or grouped nodules[1]. It is the second most common type of cutaneous T-cell lymphoma, usually skin-limited disease and most frequently affects the trunk, face and extremities. In about 10% of the patients, it involves the regional lymph nodes as extracutaneous dissemination[2]. Histologically, the tumour lesions show a diffuse infiltrate containing large-sized T lymphocytes with the morphology of anaplastic cells with oval, round, or irregular nuclei, prominent eosinophilic nucleoli and abundant cytoplasm, but there is no epidermotrophism[3]. PCALCL has no expression of anaplastic lymphoma kinase (ALK) and does not have gene rearrangements involving the *ALK* gene[4]. The main differential diagnosis of PCALCL is lymphomatoid papulosis (LyP) because their morphologic and immunophenotypic features overlap significantly and as no biomarker to date has been found to reliably distinguish these entities. It is essential to correlate the pathologic findings with the clinical history. The clinical behaviour of LyP is characterised by recurrent and regressing crops of papules and nodules that aids the distinction from PCALCL[5].

Case Report

We presented a 52-year-old male with ulcerated skin tumour mass (2.0 x 2.0 x 0.8 cm) at dorsal aspect of left hand near the base of little thumb (*Figure 1A*) and one regional lymph node enlargement in left bicep muscle. The patient noticed the small nodule underneath the left little thumb of the left hand. It was gradually increased within three months and became ulcerated on the surface. During the clinical course at three months, he noticed that there was enlargement of lymph node in the left bicep muscle. The patient denied presence of fever, weight loss or night sweats accompanying his ulcerated mass. Surgical excision of tumour mass and removal of lymph node were done due to suspicious nature of this ulcerating mass and the first pathological report was non-Hodgkin lymphoma (NHL) infiltration in skin and lymph node.

He subsequently presented to the Department of Clinical Haematology, Yangon General Hospital for further assessment and management. H&E slides were reviewed, and skin tumour mass showed diffuse lymphomatous infiltrate in the dermal portion containing cohesive sheets of neoplastic medium to large cells mixed with few inflammatory cells and histiocytes (*Figure 2A*). There was no epidermotropism. Anaplastic large tumour cells had oval, round or

irregular nuclei, prominent eosinophilic nucleoli and abundant cytoplasm (*Figure 2B*). Reactive lymphocytes were present in the edge of ulcer and periphery.

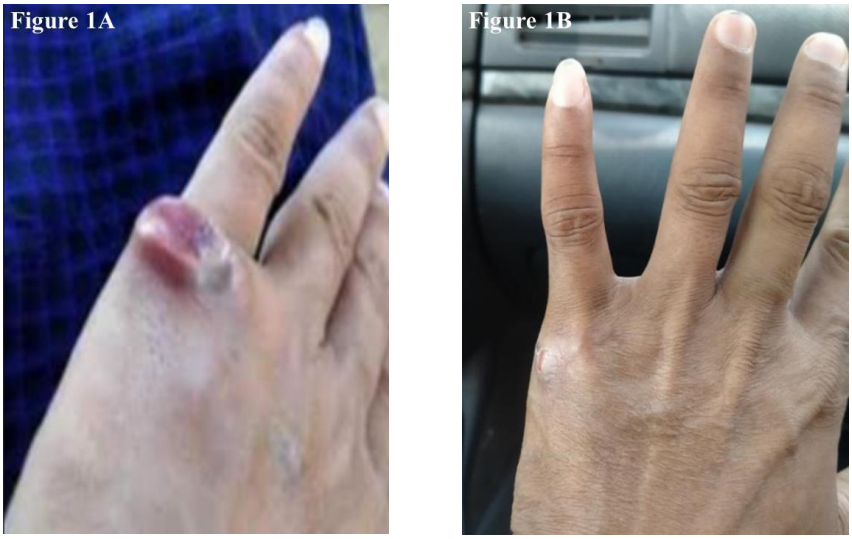

Figure 1 A 2.0 x 2.0 x 1.0 cm of ulcerated mass was developed at the base of little finger of left hand **(A)**. Healed lesion was present after 4th cycle of chemotherapy **(B)**.

Based on morphology, immunohistochemical stainings of CD3, C20, CD30, EMA, CD4, CD5, CD8, ALK, TIA1, MUM1, Ki67 and EBV/LMP1 were done. Tumour cells were strongly positive for CD3 and CD30 (*Figures 2C and 2D*). They were also positive for MUM1 and High Ki67 expression. Heterogenous expression of CD4 and CD8 were noted. They were negative for CD20, CD5, EMA, TIA1, ALK and EBV/LMP1 and it matched with primary cutaneous anaplastic large cell lymphoma. Regional lymph node showed the same morphology and the large neoplastic cells had strong expression of CD3 and CD30 (*Figure 3*).

After the surgical excision and four cycles of chemotherapy (CHOP), the lesion became cured (*Figure 1B*).

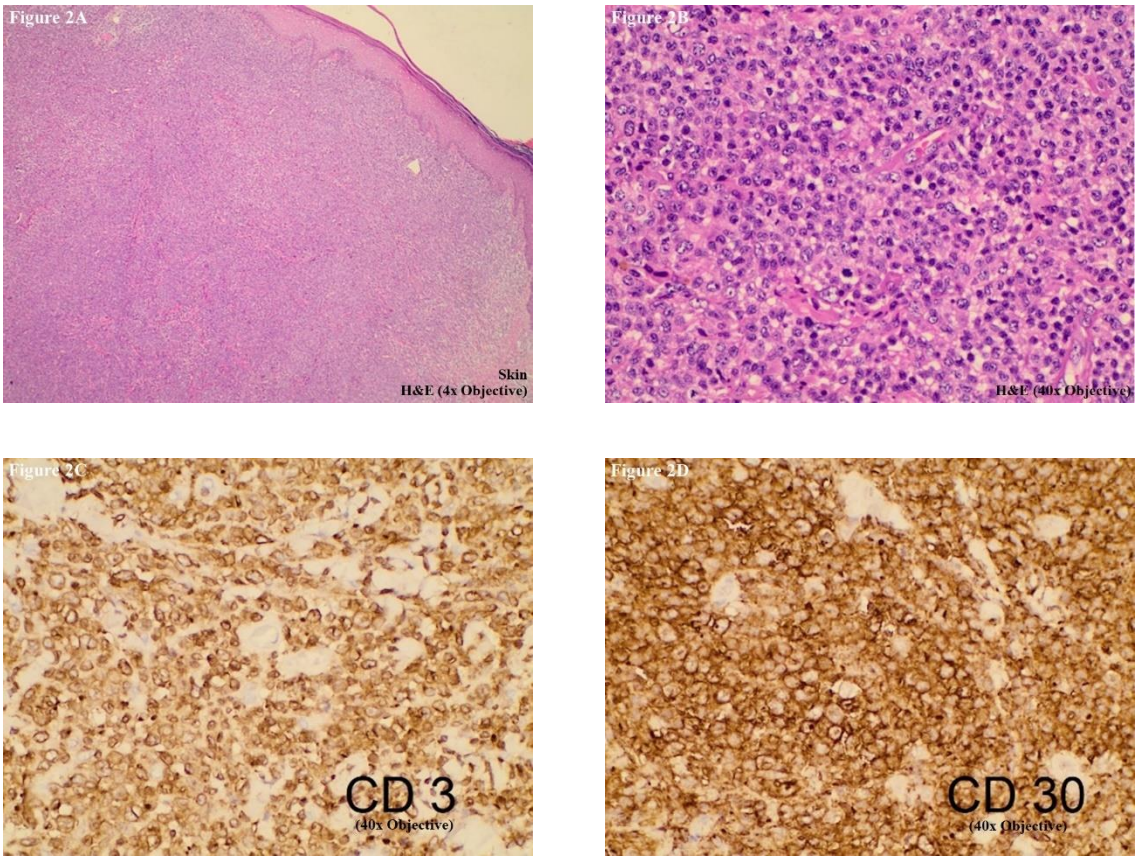

Figure 2 PCALCL. The skin tissue microscopically revealed cohesive sheet of medium- to large-sized neoplastic lymphoid cells in the dermis without features of epidermotrophism **(A)**. The infiltrating anaplastic tumour cells had abundant cytoplasm with oval, round, or irregular nuclei and prominent eosinophilic nucleoli **(B)**. These large tumour cells yielded positive immunoexpression of CD3 **(C)** and CD30 **(D)**.

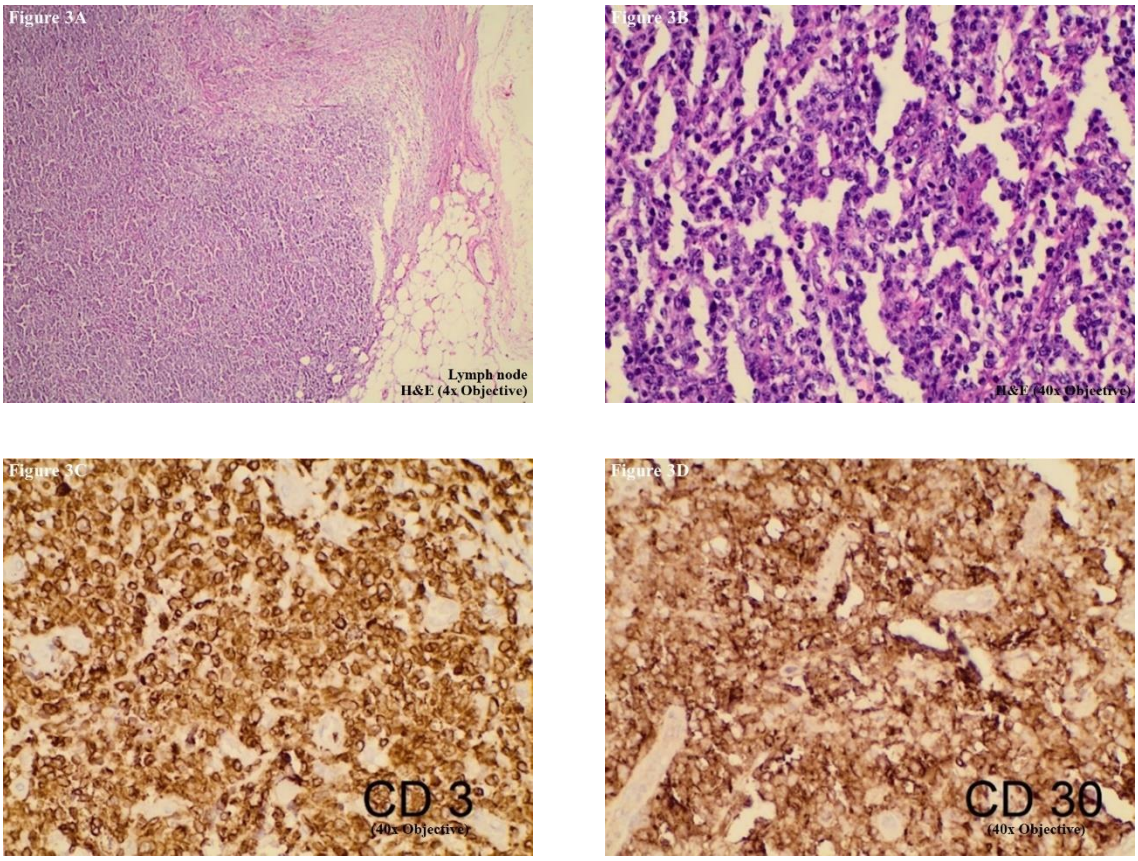

Figure 3 Regional lymph node involvement by PCALCL. Lymphoid architecture was totally distorted and was involved with diffuse cohesive sheet of anaplastic large cells **(A)**. The anaplastic large cells had moderate amount of eosinophilic cytoplasm with oval, round or irregular nuclei **(B)**. These large tumour cells yielded positive immunoexpression of CD3 **(C)** and CD30 **(D)**.

Discussion

According to the WHO 2017 revised 4th edition, primary cutaneous anaplastic large cell lymphoma (PCALCL) is the second most common type of cutaneous T-cell lymphoma, the median patient age is 60 years and male to female ratio is 2 – 3 : 1[2]. It is composed of large cells with an anaplastic, pleomorphic or immunoblastic cytomorphology and more than 75% of the tumour cells express the CD30 antigen[2,3]. Among the other type of peripheral T-cell lymphoma, the incidence of PCALCL is 1.7% and most patients present with solitary or localised nodules, papules or plaques[3]. The lesions may persist many weeks to months and reach to several centimetres, and the nodules may ulcerate over time. They can regress in 50% of patients. 20% of the patients may present with multifocal lesions. 10% of the patients will have extracutaneous dissemination[4,5]. Regional lymph node involvement does not necessarily indicate the presence of systemic disease, as pathologic involvement of local nodes alone does not impact the prognosis in patients with PCALCL. Patients with involvement of regional lymph nodes and patients presenting with multifocal skin lesions have a prognosis like that of patients with only skin lesions[6].

Histologically, large CD30-positive tumour cells proliferate as diffuse cohesive sheets. There is no epidermotropism and if seen, it is particularity marked in cases of DUSP22-IRF4 rearrangement[7]. The tumour cells have anaplastic features, i.e. abundant cytoplasm, round, oval or irregular shaped nuclei and prominent eosinophilic nucleoli[8].

The differential diagnosis includes Lymphomatoid papulosis (LyP), cutaneous involvement of systemic anaplastic large cell lymphoma (ALCL) and transformed mycosis fungoides[9]. LyP is a chronic, recurrent, self-healing skin disease compared to PCALCL[2,9]. LyP is less commonly a solitary lesion. In contrast to LyP, most cases of PCALCL present as solitary lesions; however, generalised involvement of the skin may be seen[10]. Therefore, the clinical appearance and course are critical for the definite diagnosis. Lesions in LyP are usually smaller (< 1 cm) and resolve spontaneously within a few weeks or months and have a waxing and waning clinical course[11].

In this case report, the patient was a 52-year-old male with ulcerated skin tumour mass more than one cm size. This presentation was compatible with the above-mentioned studies. The CD30-positive anaplastic tumour cells were mainly in the dermis and no epidermotropism as usual cases in other studies. Unlike systemic anaplastic large cell lymphoma, PCALCL does not express EMA or ALK protein[10,12]. In our case, the tumour cells were positive for CD3, CD30, MUM1 and Ki67 but negative for EMA, ALK and other markers. This was good accordance with

the features of PCALCL. Patients with PCALCL should not have clinical history or evidence of mycosis fungoides. A diagnosis of mycosis fungoides with large cell transformation is likely whether tumour cells are CD30-positive or CD30-negative[13]. The patient in our case report had neither clinical evidence nor clinical history of mycosis fungoides. He noticed that the solitary small tumour was developed, gradually increase in size up to 2.0 x 2.0 x 0.8 cm within three months. It also showed redness and became ulceration. Regional lymph node enlargement in left bicep muscle was noticed in three month of tumour development. The clinical course, histology and immunohistochemistry confirmed that this was involved by primary cutaneous anaplastic large cell lymphoma. Regional lymph node enlargement as an extracutaneous dissemination occurs in about 10% of patients[2,14]. In our case, the patient developed the regional lymph node enlargement during three month of clinical course and its histology showed the same tumour cells of skin nodule. These cells strongly expressed CD3 and CD30.

PCALCL is an indolent disease and localised lesion can be treated with surgical excision and radiation[15]. The multiple recurrence of lesions may warrant systemic therapy[5,15]. Patients with widespread lesions may require multi-agent chemotherapy like CHOP[15]. In our case, the patient had cutaneous lesion and regional lymph node enlargement, he got surgical excision and CHOP treatment. After 4th cycle of treatment, his lesion was cured.

Conclusion

The real incidence of PCALCL in Myanmar is unknown because of lack of reported cases. This is the first report in Myanmar and highlights the importance of early diagnosis and proper management for the disease. The definite diagnosis was made by careful histopathological examination with immunohistochemistry. Most of the cases are skin limited but it needs close monitoring due to potential risk of extracutaneous spread.

Ethical Statement

The authors have no ethical conflicts to disclose. Informed consent was obtained from the patient.

Author Contributions

Win Myat Oo performed the concept designing, laboratory diagnosis by histologic morphology, immunohistochemical study and confirmation of the case diagnosis. Sein Win performed the case investigation, case review and clinical management. Nyein Chan Aung performed the literature search and manuscript preparation. The case was conducted in Department of Clinical Haematology, Yangon General Hospital.

References

(1). Cesar GS, Joe Ensor, Akshjot Puri, Jasleen K Randhawa, Shilpan S Shah, Sai Ravi Kiran Pingali. Primary cutaneous anaplastic large cell lymphoma: Surveillance, Epidemiology and End results database Analysis from 2005-2016: Blood 2019 Nov 13; 134 (Supplement 1):4022.

(2). Swerdlow SH, Campo E, Harris NL, Jaffe ES, Pileri SA, Stein H, Thiele J. WHO Classification of Tumours of Hematopoietic and Lymphoid Tissues. Revised 4th ed. Lyon, France: IARC Press, 2017; pp. 395–396.

(3). de Oliveira LSR, Nobrega MP, Monteiro MG, et al. Primary cutaneous anaplastic large cell lymphoma—case report. An Bras Dermatol 2013;88 (6 suppl 1):132–5.

(4). Nerissa Moodley, Patiswa Nombona, Anisa Mosam. Primary cutaneous anaplastic large cell lymphoma—case report. Dermatopathology 2019; 6:163–169.

(5). Brown RA, Fernandez-Pol S, Kim J. Primary cutaneous anaplastic large cell lymphoma. J Cutan Pathol. 2017 Jun;44(6):570–7.

(6). Bekkenk MW, Geelen FA, van Voorst Vader PC, et al. Primary and secondary cutaneous CD30(+) lymphoproliferative disorders: a report from the Dutch Cutaneous Lymphoma Group on the long-term follow-up data of 219 patients and guidelines for diagnosis and treatment. Blood. 2000 Jun; 95(12):3653–61.

(7). Onaindia A, Montes-Moreno S,Rodriguez-Pinilla SM, et al. Primary cutaneous anaplastic large cell lymphomas with 6p25.3 rearrangement exhibit particular histological features. Histopathology. 2015; 66:846-55. PMID:25131361.

(8). Willemze R, Jaffe ES, Burg G, et al. WHO-EORTC classification for cutaneous lymphomas. Blood.2005; 105:3768-85. PMID:15692063.

(9). Bolognia JL, Schaffer JV, Cerroni L, editors. Dermatology. Volume 2. 4th ed, revised. New York: Elsevier; 2018. pp. 2127–47.

(10). DeCoteau J, Butmarc J, Kinney M, Kadin M. The t(2;5) chromosomal translocation is not a common feature of primary cutaneous CD30+ lymphoproliferative disorders: comparison with anaplastic large-cell lymphoma of nodal origin. Blood 1996;87: 3437-41.

(11). Kempf W, Kerl K, Mitteldorf C. Cutaneous CD30-positive T-cell lymphoproliferative disorders-clinical and histopathologic features, differential diagnosis, and treatment. Semin Cutan Med Surg. 2018 Mar;37(1):24–9.

(12). de Bruin PC, Beljaards RC, van Heerde P, et al. Differences in clinical behaviour and immunophenotype between primary cutaneous and primary nodal anaplastic large cell lymphoma of T-cell or null cell phenotype. Histopathology. 1993; 23:127-35. PMID:8406384.

(13). Benner MF, Jansen PM, Vermeer MH, et al. Prognostic factors in transformed mycosis fungoides: a retrospective analysis of 100 cases. Blood. 2012; 119:1643-9. PMID:22160616.

(14). Dawn G, Morrison A, Morton R, Bilsland D, Jackson R. Co-existent primary cutaneous anaplastic large cell lymphoma and lymphomatoid papulosis.Clin Exp Dermatol. 2003 Nov;28(6):620–4.

(15). Liu HL, Hoppe RT, Sabine Kohler, et al., CD30+ cutaneous lymphoproliferative disorders: the Stanford experience in lymphomatoid papulosis and primary cutaneous anaplastic large cell lymphoma. J Am Acad Dermatol, 2003. 49(6): p. 1049-58.

APPENDIX 1
INFORMATION FOR AUTHORS

All authors listed in a paper submitted to Asian Archives of Pathology (AAP) must have contributed substantially to the work. It is the corresponding author who takes responsibility for obtaining permission from all co-authors for the submission. When submitting the paper, the corresponding author is encouraged to indicate the specific contributions of all authors (the author statement, with signatures from all authors and percentage of each contribution can be accepted). Examples of contributions include: designed research, performed research, contributed vital new reagents or analytical tools, analysed data, and wrote the paper. An author may list more than one type of contribution, and more than one author may have contributed to the same aspect of the work.

Authors should take care to exclude overlap and duplication in papers dealing with related materials. See also paragraph on Redundant or Duplicate Publication in "Uniform Requirements for Manuscripts Submitted to Biomedical Journals" at http://www.icmje.org/index.html.

The submitted manuscripts will be reviewed by three members of the Editorial Board or three expert reviewers from different institutions. At the discretion of the Editorial Board, the manuscripts may be returned immediately without full review, if deemed not competitive or outside the realm of interests of the majority of the readership of the Journal. The decision (reject, invite revision, and accept) letter will be coming from the Editorial Board who has assumed responsibility for the manuscript's review. The editor's decision is based not just on technical merit of the work, but also on other factors such as the priority for publication and the relevance to the Journal's general readership. All papers are judged in relation to other submissions currently under consideration.

Categories of Manuscripts

1. **Letters to the Editor**

   The letters to the editor are the reactions to any papers published in AAP. These letters will be reviewed by the Editorial Board and sent to the authors of the original paper with an invitation to respond. Letters and eventual responses will be published together, when appropriate.

- *Word Count: 300 – 500 words (excluding references and figure or table legends)*
- *Abstract: Not required*
- *References: Maximum of 10*
- *Figure or Table: Maximum of 1 (if needed)*

2. Original Articles

The original articles are the researches describing the novel understanding of anatomical pathology, clinical pathology (laboratory medicine), forensic medicine (legal medicine or medical jurisprudence), molecular medicine or pathobiology. Systematic reviews, meta-analyses and clinical trials are classified as articles. The articles should be clearly and concisely written in the well-organised form (see ***Organisation of Manuscripts***): abstract; introduction; materials and methods; results; discussion; and conclusions. The manuscripts that have passed an initial screening by the Editorial Board will be reviewed by two or more experts in the field.

- *Word Count: 3,000 – 5,000 words (excluding abstract, references, and figure or table legends)*
- *Structured Abstract (see* ***Organisation of Manuscripts****): 150 – 200 words*
- *References: Maximum of 150*
- *Figures or Tables: Maximum of 6*

3. Review Articles

The review articles are generally invited by the Editor-in-Chief. They should focus on a topic of broad scientific interest and on recent advances. These articles are peer-reviewed before the final decision to accept or reject the manuscript for publication. Therefore, revisions may be required.

- *Word Count: 3,000 – 5,000 words (excluding abstract, references, and figure or table legends)*
- *Unstructured Abstract: 150 – 200 words*
- *References: Maximum of 150*
- *Figures or Tables: Maximum of 4*

4. Case Reports

AAP limits publication of case reports to those that are truly novel, unexpected or unusual, provide new information about anatomical pathology, clinical pathology (laboratory medicine) or forensic medicine (legal medicine or medical jurisprudence). In addition, they must have educational value for the aforementioned fields. The journal will not consider case reports describing preventive or therapeutic interventions, as these generally require stronger evidence. Case reports that involve a substantial literature review should be submitted as a review article. The submitted case reports will undergo the usual peer-reviewed process.

- *Word Count: 1,200 – 2,000 words (excluding abstract, references, and figure or table legends)*
- *Unstructured Abstract: 150 – 200 words*
- *References: Maximum of 20*
- *Figures or Tables: Maximum of 4*

5. Case Illustrations

Case illustrations are aimed to provide education to readers through multidisciplinary clinicopathological discussions of interesting cases. The manuscript consists of a clinical presentation or description, laboratory investigations, discussion, final diagnosis, and up to 5 take-home messages (learning points). Regarding continuous learning through self-assessment, each of the case illustrations will contain 3 – 5 multiple choice questions (MCQs) with 4 – 5 suggested answers for each question. These MCQs are placed after the final diagnosis and the correct answers should be revealed after the references. The questions and take-home messages (learning points) are included in the total word count. The manuscripts that have passed an initial screening by the Editorial Board will be reviewed by two experts in the field.

- *Word Count: 1,000 – 2,000 words (excluding references and figure or table legends)*
- *Abstract: Not required*
- *References: Maximum of 10*
- *Figures: Maximum of 2*
- *Tables: Maximum of 5*

6. Technical Notes

The technical notes are brief descriptions of scientific techniques used in the anatomical pathology, clinical pathology (laboratory medicine), forensic medicine (legal medicine or medical jurisprudence), molecular medicine or pathobiology. The submitted manuscripts are usually peer-reviewed.

- *Word Count: Maximum of 1,000 words (excluding references and figure or table legends)*
- *Abstract: Not required*
- *References: Maximum of 5*
- *Figures or Tables: Maximum of 2*

Organisation of Manuscripts

1. General Format

The manuscripts written in English language are preferable. However, Thai papers are also acceptable, but their title pages, abstracts, and keywords must contain both Thai and English. These English and Thai manuscripts are prepared in A4-sized Microsoft Word documents with leaving 2.54-cm (1-inch) margins on all sides. All documents are required to be aligned left and double-spaced throughout the entire manuscript. The text should be typed in 12-point regular Times New Roman font for English manuscript and 16-point regular TH SarabunPSK font for Thai manuscript.

The running titles of English and Thai manuscripts are placed in the top left-hand corner of each page. They cannot exceed 50 characters, including spaces between words and punctuation. For the header of English paper, the running title will be typed in all capital letters. The page number goes on the top right-hand corner.

Footnotes are not used in the manuscripts, but parenthetical statements within text are applied instead and sparingly. Abbreviations should be defined at first mention and thereafter used consistently throughout the article. The standard abbreviations for units of measure must be used in conjunction with numbers.

All studies that involve human subjects should not mention subjects' identifying information (e.g. initials) unless the information is essential for scientific purposes and the patients (or parents or guardians) give written informed consent for publication.

2. Title Page

The title page is the first page of the manuscripts and must contain the following:

- The title of the paper (not more than 150 characters, including spaces between words)
- The full names, institutional addresses, and email addresses for all authors (If authors regard it as essential to indicate that two or more co-authors are equal in status, they may be identified by an asterisk symbol with the caption "These authors contributed equally to this work" immediately under the address list.)
- The name, surname, full postal address, telephone number, facsimile number, and email address of the corresponding author who will take primary responsibility for communication with AAP.
- Conflict of interest statement (If there are no conflicts of interest for any author, the following statement should be inserted: "The authors declare that they have no conflicts of interest with the contents of this article.")

3. Abstract

A structured form of abstract is used in all Original Article manuscripts and must include the following separate sections:

- *Background: The main context of the study*
- *Objective: The main purpose of the study*
- *Materials and Methods: How the study was performed*
- *Results: The main findings*
- *Conclusions: Brief summary and potential implications*
- *Keywords: 3 – 5 words or phrases (listed in alphabetical order) representing the main content of the article*

4. Introduction

The Introduction section should clearly explain the background to the study, its aims, a summary of the existing literature and why this study was necessary or its contribution to the field.

5. Materials and Methods

The Materials and Methods section must be described in sufficient detail to allow the experiments or data collection to be reproduced by others. Common routine methods that have been published in detail elsewhere should not be described in detail. They need only be described in outline with an appropriate reference to a full description. Authors should provide the names of the manufacturers and their locations for any specifically named medical equipment and instruments, and all chemicals and drugs should be identified by their systematic and pharmaceutical names, and by their trivial and trade names if relevant, respectively. Calculations and the statistical methods employed must be described in this section.

All studies involving animal or human subjects must abide by the rules of the appropriate Internal Review Board and the tenets of the recently revised Helsinki protocol. Hence, the manuscripts must include the name of the ethics committee that approved the study and the committee's reference number if appropriate.

6. Results

The Results section should concisely describe the findings of the study including, if appropriate, results of statistical analysis which must be presented either in the text or as tables and figures. It should follow a logical sequence. However, the description of results should not simply repeat the data that appear in tables and figures and, likewise, the same data should not be displayed in both tables and figures. Any chemical equations, structural formulas or mathematical equations should be placed between successive lines of text. The authors do not discuss the results or draw any conclusions in this section.

7. Discussion

The Discussion section should focus on the interpretation and the significance of the findings against the background of existing knowledge. The discussion should not repeat information in the results. The authors will clearly identify any aspects that are novel. In addition, there is the relation between the results and other work in the area.

8. Conclusion

The Conclusion section should state clearly the main summaries and provide an explanation of the importance and relevance of the study reported. The author will also describe some indication of the direction future research should take.

9. Acknowledgements

The Acknowledgements section should be any brief notes of thanks to the following:

- *Funding sources*
- *A person who provided purely technical help or writing assistance*
- *A department chair who provided only general support*
- *Sources of material (e.g. novel drugs) not available commercially*

Thanks to anonymous reviewers are not allowed. If you do not have anyone to acknowledge, please write "Not applicable" in this section.

10. References

The Vancouver system of referencing should be used in the manuscripts. References should be cited numerically in the order they appear in the text. The authors should identify references in text, tables, and legends by Arabic numerals in parentheses or as superscripts. Please give names of all authors and editors. The references should be numbered and listed in order of appearance in the text. The names of all authors are cited when there are six or fewer. When there are seven or more, only the first three followed by "et al." should be given. The names of journals should be abbreviated in the style used in Index Medicus (see examples below). Reference to unpublished data and personal communications should not appear in the list but should be cited in the text only (e.g. A Smith, unpubl. Data, 2000).

- *Journal article*
  1. Sibai BM. Magnesium sulfate is the ideal anticonvulsant in preeclampsia – eclampsia. Am J Obstet Gynecol 1990; 162: 1141 – 5.
- *Books*
  2. Remington JS, Swartz MN. Current Topics in Infectious Diseases, Vol 21. Boston: Blackwell Science Publication, 2001.

- *Chapter in a book*

  3. Cunningham FG, Hauth JC, Leveno KJ, Gilstrap L III, Bloom SL, Wenstrom KD. Hypertensive disorders in pregnancy. In: Cunningham FG, Hauth JC, Leveno KJ, Gilstrap L III, Brom SL, Wenstrom KD, eds. Williams Obstetrics, 22nd ed. New York: McGraw-Hill, 2005: 761 – 808.

11. Tables

The tables should be self-contained and complement, but without duplication, information contained in the text. They should be numbered consecutively in Arabic numerals (Table 1, Table 2, etc.). Each table should be presented on a separate page with a comprehensive but concise legend above the table. The tables should be double-spaced and vertical lines should not be used to separate the columns. The column headings should be brief, with units of measurement in parentheses. All abbreviations should be defined in footnotes. The tables and their legends and footnotes should be understandable without reference to the text. The authors should ensure that the data in the tables are consistent with those cited in the relevant places in the text, totals add up correctly, and percentages have been calculated correctly.

12. Figure Legends

The legends should be self-explanatory and typed on a separate page titled "Figure Legends". They should incorporate definitions of any symbols used and all abbreviations and units of measurement should be explained so that the figures and their legends are understandable without reference to the text.

If the tables or figures have been published before, the authors must obtain written permission to reproduce the materials in both print and electronic formats from the copyright owner and submit them with the manuscripts. These also follow for quotes, illustrations, and other materials taken from previously published works not in the public domain. The original resources should be cited in the figure captions or table footnotes.

13. Figures

All illustrations (line drawings and photographs) are classified as figures. The figures should be numbered consecutively in Arabic numerals (Figure 1, Figure 2, etc.). They are submitted electronically along with the manuscripts. These figures should be referred to

specifically in the text of the papers but should not be embedded within the text. The following information must be stated to each microscopic image: staining method, magnification (especially for electron micrograph), and numerical aperture of the objective lens. The authors are encouraged to use digital images (at least 300 d.p.i.) in .jpg or .tif formats. The use of three-dimensional histograms is strongly discouraged when the addition of these histograms gives no extra information.

14. Components

14.1. Letters to the Editor

The Letter to the Editor manuscripts consist of the following order:

- *Title Page*
- *Main Text*
- *References*
- *Table (if needed)*
- *Figure Legend (if needed)*
- *Figure (if needed)*

14.2. Original Articles

The Original Article manuscripts consist of the following order:

- *Title Page*
- *Structured Abstract*
- *Introduction*
- *Materials and Methods*
- *Results*
- *Discussion*
- *Conclusions*
- *Acknowledgements*
- *References*
- *Table (s)*
- *Figure Legend (s)*
- *Figure (s)*

14.3. Review Articles

The Review Article manuscripts consist of the following order:

- *Title Page*
- *Unstructured Abstract*
- *Introduction*
- *Main Text*
- *Conclusions*
- *Acknowledgements*
- *References*
- *Table (s)*
- *Figure Legend (s)*
- *Figure (s)*

14.4. Case Reports

The Case Report manuscripts consist of the following order:

- *Title Page*
- *Unstructured Abstract*
- *Introduction*
- *Case Description*
- *Discussion*
- *Conclusions*
- *Acknowledgements*
- *References*
- *Table (s)*
- *Figure Legend (s)*
- *Figure (s)*

14.5. Case Illustrations

The Case Illustration manuscripts consist of the following order:

- *Title Page*
- *Clinical Presentation or Description*
- *Laboratory Investigations*
- *Discussion*
- *Final Diagnosis*
- *Multiple Choice Questions (MCQs)*
- *Take-Home Messages (Learning Points)*

- *Acknowledgements*
- *References*
- *Correct Answers to MCQs*
- *Table (s)*
- *Figure Legend (s)*
- *Figure (s)*

14.6. Technical Notes

The Technical Note manuscripts consist of the following order:

- *Title Page*
- *Introduction*
- *Main text*
- *Conclusions*
- *Acknowledgements*
- *References*
- *Table (s)*
- *Figure Legend (s)*
- *Figure (s)*

Proofreading

The authors of the accepted manuscripts will receive proofs and are responsible for proofreading and checking the entire article, including tables, figures, and references. These authors should correct only typesetting errors at this stage and may be charged for extensive alterations. Page proofs must be returned within 48 hours to avoid delays in publication.

Revised Manuscripts

In many cases, the authors will be invited to make revisions to their manuscripts. The revised manuscripts must generally be received by the Editorial Board within 3 months of the date on the decision letter or they will be considered a new submission. An extension can sometimes be negotiated with the Editorial Board.

APPENDIX 2
BENEFITS OF PUBLISHING WITH ASIAN ARCHIVES OF PATHOLOGY

Asian Archives of Pathology (AAP) is an open access journal. Open Access makes your works freely available to everyone in the world. It provides a significant boost to the readership of your articles, and has been shown to have an increase in positive influence on citations and reuse. Hence, open-access leads to more recognition for our esteemed authors.

The journal has been sponsored by the Royal College of Pathologists of Thailand. We have the policy to disseminate the verified scientific knowledge to the public on a non-profit basis. Hence, we have not charged the authors whose manuscripts have been submitted or accepted for publication in our journal.

Since AAP is also a peer-reviewed journal, the submitted manuscripts will be reviewed by three members of the Editorial Board or three expert reviewers from different institutions. The decision on these manuscripts is processed very fast without any delay and in shortest possible time. The processing period is 1 – 2 weeks. These decisions of the reviewers are unbiased and the decision (reject, invite revision, and accept) letter coming from the Editorial Board is always conveyed to the authors.

APPENDIX 3
SUBMISSION OF THE MANUSCRIPTS

Step 1: Access www.asianarchpath.com

Step 2: If you did not register before, please create an account first.

Step 3: Login with your username and password.

Step 4: Click the "+ New Submission" button on the upper right-hand side of the page.

Step 5: Proceed to fill up the Submission Form online and follow the directions given therein.

Step 6: Upload your manuscript file (s).

Step 7: Re-check the content of your manuscript (s) and the uploaded file (s) more carefully prior to the submission. If you have submitted your manuscript file (s) incorrectly, you must contact Editor-in-Chief of Asian Archives of Pathology immediately. The Editor-in-Chief can clear the incorrect attempt and allow you another submission.

Step 8: Click the "Submit Manuscript" button under Important Notice.

If you have any further enquiries, please do not hesitate to contact the Journal.

APPENDIX 4
CONTACT THE JOURNAL

The Editorial Office of Asian Archives of Pathology

Department of Pathology, Floor 6, Her Royal Highness Princess Bejaratana Building
Phramongkutklao College of Medicine
317 Rajavithi Road, Rajadevi, Bangkok 10400 Thailand

Telephone: +66 (0) 90 132 2047

Fax: +66 (0) 2 354 7791

Email: editor@asianarchpath.com

APPENDIX 5
SUPPORT THE JOURNAL

Asian Archives of Pathology (AAP) has a mission of disseminating the unbiased and reliable medical knowledge on a non-profit basis. If you consider that this journal is useful for the public, you can support us by submitting your advertisements via the contact information below.

Assistant Professor Dr Chetana Ruangpratheep
The Editorial Office of Asian Archives of Pathology
Department of Pathology, Floor 6, Her Royal Highness Princess Bejaratana Building
Phramongkutklao College of Medicine
317 Rajavithi Road, Rajadevi, Bangkok 10400 Thailand
Telephone: +66 (0) 90 132 2047
Fax: +66 (0) 2 354 7791
Email: editor@asianarchpath.com

Every support, small or big, can make a difference.

Thank you

Assistant Professor Dr Chetana Ruangpratheep
MD, FRCPath (Thailand), MSc, PhD
Editor-in-Chief of Asian Archives of Pathology

ACADEMIC MEETINGS AND CONFERENCES

Announcements of academic meetings and conferences that are of interest to the readers of Asian Archives of Pathology (AAP) should be sent to the Editor-in-Chief at least 3 months before the first day of the month of issue. The contact information is shown below.

Assistant Professor Dr Chetana Ruangpratheep

The Editorial Office of Asian Archives of Pathology

Department of Pathology, Floor 6, Her Royal Highness Princess Bejaratana Building

Phramongkutklao College of Medicine

317 Rajavithi Road, Rajadevi, Bangkok 10400 Thailand

Telephone: +66 (0) 90 132 2047

Fax: +66 (0) 2 354 7791

Email: editor@asianarchpath.com

WHAT IS INSIDE THIS ISSUE?

Letter to the Editor:

Original Article:

Case Report: