ASIAN ARCHIVES OF PATHOLOGY

THE OFFICIAL JOURNAL OF THE ROYAL COLLEGE OF PATHOLOGISTS OF THAILAND

Volume 4
Number 1
January – March 2022

INDEX COPERNICUS INTERNATIONAL

Print ISSN: 1905-9183

Online ISSN: 2673-0499

EDITORIAL BOARD

ABOUT THE JOURNAL

Aims and Scope

Asian Archives of Pathology (AAP) is an open access, peer-reviewed journal. The journal was first published in 2002 under the Thai name "วารสารราชวิทยาลัยพยาธิแพทย์แห่งประเทศไทย" and English name "Journal of the Royal College of Pathologists of Thailand". The journal is a publication for workers in all disciplines of pathology and forensic medicine. In the first 3 years (volumes), the journal was published every 4 months. Until 2005, the journal has changed its name to be "Asian Archives of Pathology: The Official Journal of the Royal College of Pathologists of Thailand", published quarterly to expand the collaboration among people in the fields of pathology and forensic medicine in the Asia-Pacific regions and the Western countries.

The full articles of the journal are appeared in either Thai or English. However, the abstracts of all Thai articles are published in both Thai and English languages. The journal features letters to the editor, original articles, review articles, case reports, case illustrations, and technical notes. Diagnostic and research areas covered consist of (1) **Anatomical Pathology** (including cellular pathology, cytopathology, haematopathology, histopathology, immunopathology, and surgical pathology); (2) **Clinical Pathology (Laboratory Medicine)** [including blood banking and transfusion medicine, clinical chemistry (chemical pathology or clinical biochemistry), clinical immunology, clinical microbiology, clinical toxicology, cytogenetics, parasitology, and point-of-care testing]; (3) **Forensic Medicine (Legal Medicine or Medical Jurisprudence)** (including forensic science and forensic pathology); (4) **Molecular Medicine** (including molecular genetics, molecular oncology, and molecular pathology); (5) **Pathobiology**; and (6) **Pathophysiology**.

All issues of our journal have been printed in hard copy since the beginning. Around the late 2014, we developed our website (www.asianarchpath.com) in order to increase our visibility. We would like to acknowledge that our journal has been sponsored by the Royal College of Pathologists of Thailand. We have the policy to disseminate the verified scientific knowledge to the public on a non-profit basis. Hence, we have not charged the authors whose manuscripts have been submitted or accepted for publication in our journal.

On the other hand, if any authors request a printed copy of the journal issue containing the articles, each of the copied journals costs 450 bahts for Thai authors and 30 United States dollars (USD) for international authors.

Publication Frequency

Four issues per year

Disclaimer

The Royal College of Pathologists of Thailand and Editorial Board cannot be held responsible for errors or any consequences arising from the use of information contained in Asian Archives of Pathology. It should also be noted that the views and opinions expressed in this journal do not necessarily reflect those of The Royal College of Pathologists of Thailand and Editorial Board.

MANUSCRIPT REVIEWERS

CONTENTS

LETTER TO THE EDITOR

กลุ่มโปรตีนแมททริกซ์เมทัลโลโปรตีเนส (เอ็มเอ็มพีเอส) และการสมานบาดแผลที่เกี่ยวข้องกับภาวะเบาหวาน [Matrix metalloproteinases (MMPs) and diabetic wound healing]

ภัสรา อาณัติ

ภาควิชาชีวเคมี ชั้น 5 อาคารเจ้าฟ้าเพชรรัตน วิทยาลัยแพทยศาสตร์พระมงกุฎเกล้า
เลขที่ 317 ถนนราชวิถี แขวงทุ่งพญาไท เขตราชเทวี จังหวัดกรุงเทพมหานคร รหัสไปรษณีย์ 10400
โทรศัพท์: +66 (0) 83 619 8689 Email: pasra@pcm.ac.th, pasra@hotmail.com

ผลประโยชน์ทับซ้อน: ผู้นิพนธ์แจ้งให้ทราบโดยทั่วกันว่าไม่มีผลประโยชน์ทับซ้อนในเนื้อหาของบทความนี้

ส่งต้นฉบับ: วันที่ 1 เดือนธันวาคม พ.ศ. 2564
รับลงตีพิมพ์: วันที่ 10 เดือนธันวาคม พ.ศ. 2564
ตีพิมพ์เผยแพร่: วันที่ 1 เดือนมกราคม พ.ศ. 2565

การศึกษาทางสรีรวิทยาการหายของบาดแผลปกติพบว่า เป็นปฏิกิริยาที่ทำงานร่วมกันระหว่างเซลล์และสารต่าง ๆ ได้แก่ เซลล์ผิวหนังชั้นนอก (Epidermal cells) เซลล์ผิวหนังชั้นใน (Dermal cells) สารประกอบที่อยู่ระหว่างเซลล์ (Extracellular matrix) การสร้างหลอดเลือดใหม่ (Angiogenesis) โปรตีนในเลือด (Plasma protein) สาร Cytokines รวมถึงปัจจัยในการเจริญเติบโต (Growth factors)[1] โดยกระบวนการหายของบาดแผลสามารถแบ่งออกได้เป็น 4 ระยะ ได้แก่ ระยะห้ามเลือด (Haemostasis) ระยะอักเสบ (Inflammation) ระยะแบ่งเซลล์ (Proliferation) และระยะเสริมสร้างความแข็งแรง (Remodeling) ซึ่งแต่ละระยะจะเกิดการเปลี่ยนแปลงอย่างต่อเนื่องและทับซ้อนกัน[2,3] ปัจจัยสำคัญที่ทำให้เกิดแผลเรื้อรังหรือแผลที่ยังไม่หายมี 2 ประการ คือ ปัจจัยเฉพาะที่ (Local factor) และปัจจัยทางระบบของร่างกาย (Systemic factors)[1,4] สำหรับปัจจัยเฉพาะที่ ได้แก่ การติดเชื้อ การเปื่อยนุ่มของผิวหนังรอบแผลจากสารน้ำในแผลออกมาบริเวณผิวหนังปกติรอบแผลมากเกินไป (Tissue maceration) มีสิ่งแปลกปลอมในแผล การขาดเลือดมาเลี้ยง มะเร็งที่ผิวหนัง หลอดเลือดดำผิดปกติ การชอกช้ำที่แผล (Mechanical trauma) สารพิษ การฉายรังสี หรือเป็นผลจากการรักษา (Iatrogenic) ส่วนปัจจัยทางระบบของร่างกาย ได้แก่ โรคเรื้อรัง ภาวะขาดสารอาหาร ภาวะติดสุราเรื้อรัง การใช้สาร Glucocorticoid steroids ยาเคมีบำบัด คนสูงอายุ มะเร็ง และการมีของเสียคั่งในระบบต่าง ๆ ของร่างกาย (Uraemia) แผลเรื้อรังหรือแผลที่ยังไม่หายมักมีการหยุดชะงักที่ระยะอักเสบ ระยะแบ่งเซลล์ และระยะเสริมสร้างความแข็งแรง โดยพบว่าการมีระยะอักเสบที่ยาวนานเป็นปัจจัยสำคัญที่สุดในการเกิดแผลหายช้า[5-7] นอกจากนี้แผลเรื้อรังจะมีสิ่งที่แตกต่างจากแผลปกติ คือ การเพิ่มจำนวนของ Epithelium การอักเสบ การเกิด Fibrosis และการสร้างหลอดเลือด (Capillary proliferation)[8]

ในภาวะปกติการสมานบาดแผล (Wound healing) จะมีการสร้างกลุ่มโปรตีนแมททริกซ์เมทัลโลโปรตีเนส (เอ็มเอ็มพีเอส) [Matrix metalloproteinases (MMPs)] ซึ่งเป็นกลุ่มของเอ็นไซม์ที่มีบทบาทในขบวนการจัดโครงร่างเนื้อเยื่อด้วยการย่อยสาร Extracellular matrix โดยกลุ่มโปรตีน MMPs สามารถแบ่งได้เป็นหลายชนิดขึ้นอยู่กับ Substrate เช่น โปรตีน MMP-1 (Collagenase) มีบทบาทในเรื่อง Keratinocyte migration และ Re-epithelialisation และโปรตีน MMP-9 (Gelatinase) มีบทบาทในเรื่อง Promote inflammation และช่วยเพิ่มการ Migration ของ Neutrophils ซึ่งมีโปรตีน TIMP-1 เป็นตัวควบคุมและยับยั้งการทำงานของโปรตีน MMP-1 และโปรตีน MMP-9 ทั้งนี้จากการศึกษาพยาธิสรีรวิทยาการหายของบาดแผลเรื้อรังพบว่า แผลเรื้อรังมีระดับของโปรตีน MMPs สูงกว่าในแผลเฉียบพลัน จึงทำให้เกิดความไม่สมดุลระหว่าง Proteinases และตัวยับยั้ง (Inhibitors) เมื่อมีกระบวนการ Proteolytic เพิ่มขึ้นจึงลดการควบคุมการทำลายเนื้อเยื่อ ซึ่งอาจทำให้เกิดแผลเรื้อรังและไม่หายของแผล อนึ่งแผลที่ระดับของโปรตีน MMPs สูงจะเกิดการลดการแบ่งเซลล์และการสร้างหลอดเลือดใหม่ รวมทั้งการเพิ่มการทำลาย Extracellular matrix จึงทำให้การซ่อมแซมเนื้อเยื่อทำได้ไม่ดี[1,5,6] นอกจากนี้ยังพบว่าเซลล์ Keratinocytes ของแผลเรื้อรังจะลดการปล่อยกลุ่มสารประกอบโปรตีน TIMPs อีกด้วย ซึ่งโดยทั่วไปกลุ่มสารประกอบโปรตีน TIMPs จะก่อให้เกิดความสมดุล (Counterbalance) ของกลุ่มโปรตีน MMPs[9] โดยโปรตีน TIMP-1 มีหน้าที่ในการป้องกันเนื้อเยื่อจากการถูกทำลายโดยกระบวนการ Proteolytic ซึ่งโปรตีน Epidermal TIMP-1 จะยับยั้งการทำงานของกลุ่มโปรตีน

MMPs ที่ทำลาย Epidermal basement membrane นั่นคือเมื่อระดับของกลุ่มโปรตีน TIMPs ในบาดแผลลดลงก็จะส่งผลให้แผลหายช้าได้[8]

ภาวะเบาหวาน (Diabetes mellitus) เป็นโรคเรื้อรังทางสาธารณสุขที่สำคัญโรคหนึ่งในปัจจุบัน ภาวะแทรกซ้อนที่พบบ่อยของโรคนี้ คือ การเกิดบาดแผลเรื้อรังของเบาหวานที่เท้า (Chronic diabetic foot ulcer) โดยสามารถพบได้ถึงร้อยละ 15 ของผู้ป่วยเบาหวาน และคิดเป็นร้อยละ 84 ของผู้ป่วยที่ต้องได้รับการตัดขา[10-12] สาเหตุของบาดแผลเบาหวานเกิดจากการสูญเสียสภาพของหลอดเลือดแดงขนาดใหญ่ (Macrocirculation) หลอดเลือดแดงขนาดเล็ก (Microcirculation) และระบบเส้นประสาทรับความรู้สึก (Sensory nerve) ซึ่งกลุ่มโปรตีน MMPs เป็นกลุ่มเอ็นไซม์ที่มีบทบาทสำคัญต่อการหายของแผลเรื้อรังในผู้ป่วยเบาหวาน โดยระดับของโปรตีน MMP-1 ที่เพิ่มสูงขึ้นจะช่วยในการรักษาบาดแผล ขณะที่ปริมาณโปรตีน MMP-9 ที่มากเกินไปจะทำให้เกิดอันตรายต่อบาดแผล โดยทำให้เนื้อเยื่อใหม่ที่จะเกิดขึ้นไม่สามารถถูกสร้างได้ตามปกติ[13] นอกจากนี้เมื่อเปรียบเทียบระดับของกลุ่มโปรตีน TIMPs ในบาดแผล จะพบว่าบาดแผลเรื้อรังมีระดับของกลุ่มโปรตีน TIMPs ต่ำกว่าในบาดแผลเฉียบพลัน ผลจากอัตราส่วน MMP/TIMP ที่สูงขึ้นทำให้มีการส่งเสริมการย่อยสลาย Extracellular matrix ที่มากเกินไปและเป็นผลให้ยังคงมีการอักเสบอย่างต่อเนื่อง[14] ทั้งนี้ในบาดแผลเรื้อรังจากภาวะเบาหวานจะพบปริมาณของโปรตีน MMP-1 โปรตีน MMP-8 โปรตีน MMP-9 และโปรตีน Activated MMP-2 สูงขึ้น ในขณะที่โปรตีน TIMP-2 จะมีปริมาณต่ำกว่าในบาดแผลเฉียบพลันจากสาเหตุอื่นที่ไม่ใช่ภาวะเบาหวาน (Acute wound from non-diabetics) อย่างมีนัยสำคัญทางสถิติ[15] อย่างไรก็ตามการศึกษาถึงการเปลี่ยนแปลงของระดับของกลุ่มโปรตีน MMPs ในช่วงระยะเวลาต่าง ๆ ของการเกิดการสมานแผลในบาดแผลเรื้อรังเบาหวานยังมีไม่มาก

เอกสารอ้างอิง

(1). Harding KG, Morris HL, Patel GK. Science, medicine and the future: healing chronic wounds. BMJ. 2002; 324(7330): 160-3.

(2). Beitz JM. Wound debridement: therapeutic options and care considerations. Nurs Clin North Am. 2005; 40(2): 233-49.

(3). Keast DH, Orsted H. The basic principles of wound care. Ostomy Wound Manage. 1998; 44(8): 24-8, 30-1.

(4). Hess CT, Kirsner RS. Uncover the latest techniques in wound bed preparation. Nurs Manage. 2003 Dec; 34(12): 54-6.

(5). Medina A, Scott PG, Ghahary A, Tredget EE. Pathophysiology of chronic nonhealing wounds. J Burn Care Rehabil. 2005; 26(4): 306-19.

(6). Ayello EA, Cuddigan JE. Conquer chronic wounds with wound bed preparation. Nurse Pract. 2004; 29(3): 8-25; 26-7.

(7). Bates-Jensen BM. Chronic wound assessment. Nurs Clin North Am. 1999; 34(4): 799-845.

(8). Vaalamo M, Weckroth M, Puolakkainen P, et al. Patterns of matrix metalloproteinase and TIMP-1 expression in chronic and normally healing human cutaneous wounds. Br J Dermatol. 1996; 135(1): 52-9.

(9). Quatresooz P, Henry F, Paquet P, Pierard-Franchimont C, Harding K, Pierard GE. Deciphering the impaired cytokine cascades in chronic leg ulcers (review). Int J Mol Med. 2003; 11(4): 411-8.

(10). American Diabetes Association. Diagnosis and classification of diabetes mellitus. Diabetes care 2004; 27(1): 5-10.

(11). Stanley S, Turner L. A collaborative care approach to complex diabetic foot ulceration. Br J Nurs. 2004; 13(13): 788-93.

(12). Brem H, Tomic-Canic M. Cellular and molecular basis of wound healing in diabetes. J Clin Invest. 2007; 117(5): 1219-22.

(13). Lobmann R, Ambrosch A, Schultz G, Waldmann K, Schiweck S, Lehnert H. Expression of matrix-metalloproteinases and their inhibitors in the wounds of diabetic and non-diabetic patients. Diabetologia. 2002; 45(7): 1011-6.

(14). Ravanti L, Kähäri VM. Matrix metalloproteinases in wound repair (review). Int J Mol Med. 2000; 6(4): 391-407.

(15). Muller M, Trocme C, Lardy B, Morel F, Halimi S, Benhamou PY. Matrix metalloproteinases and diabetic foot ulcers: the ratio of MMP-1 to TIMP-1 is a predictor of wound healing. Diabet Med 2008; 25(4): 419-26.

ORIGINAL ARTICLE

Examining the crucial components of quality in clinical autopsies: reflections as correlates of quality health care and implications for health professionals

Akinwumi Oluwole Komolafe[1*] and Abiola Olubusola Komolafe[2]

1 *Department of Morbid Anatomy and Forensic Medicine, Obafemi Awolowo University Teaching Hospitals Complex, Ile-Ife, Osun State, Nigeria*

2 *Department of Nursing Science, Obafemi Awolowo University, Ile-Ife, Osun State, Nigeria*

* Correspondence to: Dr Akinwumi Oluwole Komolafe, Department of Morbid Anatomy and Forensic Medicine, Obafemi Awolowo University Teaching Hospitals Complex, Ilesa Road, Ile-Ife, Osun State PMB 5538 Nigeria. Telephone: +234 803 355 7741 Email: abiolakomolafe2016@gmail.com, abikomo@oauife.edu.ng

Conflict of interest: The authors declare that they have no conflicts of interest with the contents of this article.

Submitted: *14 June 2021*
Accepted: *23 June 2021*
Published: *1 January 2022*

Abstract

The clinical autopsy is gradually becoming extinct due to the fear of litigations by clinicians who feel threatened by possible worrisome revelations through the autopsy. The aim of this study was to assess the most important components of clinical autopsies, as yardstick for assessing quality clinical practice. A retrospective review of documentations in clinical autopsy reports of 75 full post-mortem dissections were conducted. Attention was paid to the crucial components of a quality autopsy. The results revealed that 60% of the cases were males while 40% were females. The leading causes of death were raised intracranial pressure (26.7%) and septic shock (26.7%). Correct diagnoses were made in 66.7% of cases and there was 0% compliance with the guideline for clinicopathological write-up. The prime position of the post-mortem examination as the medical audit tool for the quality of care in clinical practice remains unassailable. The autopsy remains the gold standard for assessing the competence of health professionals of all levels and could provoke many questions about decisions taken and care given in the deceased patients care. Thus, the autopsy as a quality evaluation tool must measure up to the highest quality standard possible.

Keywords: clinical autopsies; diagnostic concordance with clinical practice; quality control

Introduction

The provision of quality care centres on correct clinical diagnoses. The clinical diagnoses provide guidance on patients' health problems and the care needed[1]. When clinical diagnoses are missed or incorrect, the medical and nursing care may be ineffective resulting in preventable deaths in many cases[2]. The autopsy though a gradually vanishing medical service remains the gold standard for assessing the quality of medical practice[3]. The post-mortem examination evaluates the appropriateness or otherwise of the decisions taken during the antemortem care of patients by the clinicians and other care givers[4]. The autopsy also verifies the judgements and conclusions of investigative departments such as laboratory medicine and radiology. It remains the best means of incontrovertible clinicopathological correlation. If the autopsy is an assessor of excellent and quality medical practice, then it stands to reason that the autopsy itself must conform with the highest standards possible in terms of conduct, techniques, personnel, interpretation, maintenance of the chain of custody of retained tissues, documentation, timely delivery of reports and necessary associated correspondence.

The autopsy by its pivotal position and veritable standards in assessing clinical care then needs to be consistently of the highest quality possible. The post-mortem examination is a multistage procedure consisting of several processes and stages that may not be outrightly quantifiable. The techniques of dissection, the objectivity of morphological analysis may not be easily verifiable but the documentations would in retrospect raise questions about the quality of the post-mortem examination[5]. This study being retrospective in nature could not assess all the afore-mentioned quality elements but by virtue of assessing the components of the autopsy report and documentations, the authors sought to contribute to affirming the place of quality in autopsy practice.

This study aimed to ascertain the compliance with quality control defining standards in full post-mortem examinations in patients who died on admission in the hospital.

Materials and Methods

The study was a retrospective review of clinical autopsy reports in the practice jurisdiction of pathologists of the Department of Morbid Anatomy and Forensic Medicine, Obafemi Awolowo University Teaching Hospitals Complex, Ile-Ife, Osun State, Nigeria, over 9 years (2011 – 2019). The study analysed the clinical autopsy reports in order to ascertain for documentation of the most important aspects of a quality autopsy procedure such as the

autopsy diagnosis of the primary disease that initiated the sequence of events resulting in death, clinical history, working clinical diagnoses, autopsy findings, provisional anatomical diagnoses, final anatomical diagnosis, clinicopathological correlation and cause of death. It also ascertained the correct and incorrect diagnoses based on autopsy findings, define the primary disease responsible for the sequential morphological changes in each autopsy as well as the immediate causes of death in the autopsies. All cases with incomplete data were excluded from the study and the data obtained were analysed using descriptive statistical methods.

Results

Out of the autopsy cases, only seventy-five cases met the inclusion criteria. There were 45 (60%) males and 30 (40%) females making a male to female ratio of 1.5:1. There were 50 (66.67%) cases of correct clinical diagnoses and 25 (33.33%) cases of incorrect clinical diagnoses. Thirty-two out of 75 (42.67%) cases with correct clinical diagnosis were made in males (*Tables 1 and 2*). There were 21 cases of systemic hypertension, 7 cases of perforated typhoid ileitis, 4 cases of pulmonary tuberculosis, 3 cases of renal cell carcinoma, 3 cases of hepatocellular carcinoma, 3 cases of perforated gastric ulcer, 2 cases of perforated gastric adenocarcinoma, 2 cases of pyogenic meningitis, 2 cases of liver cirrhosis, 2 cases of lobar pneumonia, 2 cases of organophosphate poisoning, 2 cases of sickle cell anaemia and one case each for submandibular abscess, subdural abscess, lung abscess, perforated colorectal carcinoma, adenosquamous carcinoma of the left lung, non-Hodgkin lymphoma, road traffic accident, perforated acute appendicitis, chronic glomerulonephritis, gestational choriocarcinoma, chronic myeloid leukaemia, acute fulminant hepatitis, multiple myeloma, intracerebral abscess, bronchopneumonia, septic abortion, intussusception, embryonal rhabdomyosarcoma, ruptured dissecting aortic aneurysm, chorioamnionitis and post-operative sepsis.

Of the causes of death, there were 20 (26.67%) cases of raised intracranial pressure, 20 (26.67%) cases of septic shock, 15 (20%) cases of pulmonary oedema, 7 (9.33%) cases of haemorrhagic shock, 5 (6.67%) cases of asphyxia, 3 (4%) cases of anaemic heart failure, one (1.33%) case each of aspiration pneumonitis, carcinomatosis, cardiogenic shock, hepatic failure and ischaemic heart disease (*Table 3*).

Table 1 Age and gender distribution of correct and incorrect clinical diagnoses. Approximately 66.67% of cases had correct clinical diagnoses and the largest percentage (42.67%) of these cases were made in males.

Age (Years old)	Clinical diagnosis (Cases)				Total (Cases)
	Correct		Incorrect		
	Male	Female	Male	Female	
0 – 10	0	1	0	1	**2**
11 – 20	3	3	1	1	**8**
21 – 30	3	2	1	3	**9**
31 – 40	5	5	1	1	**12**
41 – 50	6	1	1	2	**10**
51 – 60	9	3	1	3	**16**
61 – 70	4	3	7	1	**15**
71 – 80	2	0	1	0	**3**
Total (Cases)	**32**	**18**	**13**	**12**	**75**

Though all of 75 cases showed documentation on the biodata, clinical history, working clinical diagnosis, provisional anatomical diagnosis, final anatomical autopsy diagnosis of the primary and initiating disease condition, cause of death and clinicopathological correlation, all the cases had incomplete write-up of the clinicopathological correlation, as the reasons for wrong clinical features were not accounted for. Medicolegal issues were not mentioned. None of the reports had the documentation of the turn-around time or the official communication of the report to the clinicians by means of an autopsy correspondence.

Table 2 The discrepancy between clinical and autopsy diagnoses. Based on 25 cases of incorrect clinical diagnoses, the missed diagnoses mostly consisted of infections in the elders (particularly the seventh decade of life), malignancies and hypertensive complications.

Case	Age (Years old)	Gender	Diagnosis		Cause of Death
			Clinical	Autopsy	
1	0.04	Female	Neonatal sepsis	Bronchopneumonia	Septic Shock
2	10	Female	Sickle cell anaemia	Typhoid enteritis	Septic Shock
3	12	Female	Malaria fever	Intussusception due to massive intestinal ascariasis	Septic Shock
4	20	Male	Acute bacterial meningitis, rule-out cerebral abscess with orbital cellulitis	Frontal sinusitis with orbital cellulitis with left subdural abscess	Cerebral oedema with raised intracranial pressure
5	22	Female	Meningo-encephalitis secondary to chronic otitis media	Left subdural abscess with meningeal extension and chronic otitis media	Cerebral oedema with raised intracranial pressure
6	25	Female	Missed abortion	Disseminated tuberculosis in pregnancy with missed abortion	Anaemic heart failure
7	27	Female	Incomplete abortion	Perforated acute appendicitis	Septic Shock
8	30	Male	Post-tonsillectomy sepsis	Lung abscess	Septic Shock
9	36	Male	Massive upper GIT bleeding probably from peptic ulcer	Liver cirrhosis	Haemorrhagic Shock
10	37	Female	Severe pre-eclampsia with left lateral head swelling	Right renal cell carcinoma with scalp and intracranial metastasis	Cerebral oedema with raised intracranial pressure
11	45	Female	Chest infection	Multiple myeloma	Bronchopneumonia with respiratory failure
12	46	Male	Congestive cardiac failure secondary to delayed dilated cardiomyopathy, arrythmias and chest infection	Perforated gastric ulcer	Septic Shock
13	50	Female	Sepsis, rule-out meningitis, viral haemorrhagic fever, probably acute fulminant hepatitis and immunosuppression	Acute fulminant hepatitis with massive hepatocellular necrosis	Hepatic failure
14	52	Female	Acute coronary syndrome most likely acute myocardial infarction, rule-out acute-on-chronic kidney disease, hyperglycaemia, emergency diabetic ketoacidosis	Systemic hypertension with hypertensive heart disease, bi-ventricular heart failure	Pulmonary oedema
15	56	Female	Perforated duodenal ulcer with generalised peritonitis	Perforated typhoid ileitis	Septic Shock
16	59	Male	Chronic renal failure	Renal cell carcinoma	Aspiration pneumonitis
17	62	Male	Fungal granulomatous disease/Sezary syndrome	Non-Hodgkin's lymphoma with thoracic obstruction	Asphyxia
18	64	Male	Pulmonary emboli, rule-out myocardial infarction and pulmonary tuberculosis	Ruptured dissecting aortic aneurysm in a known hypertensive diabetics	Haemorrhagic shock
19	65	Male	Type 2 Diabetes Mellitus with non-ketotic coma precipitated by urinary tract infection, acute on chronic renal failure in a known hypertensive.	Malignant systemic hypertension with hypertensive heart disease, bi-ventricular heart failure with congestive cardiac failure.	Pulmonary oedema
20	65	Male	Probably shock	Systemic hypertension with hypertensive heart disease, bi-ventricular heart failure with congestive cardiac failure	Pulmonary oedema
21	68	Male	Type 2 Diabetes Mellitus with hyperglycaemic emergency precipitated by sepsis from urinary tract infection	Bronchopneumonia	Pulmonary oedema
22	69	Female	Left lung collapse, rule-out pulmonary tuberculosis and bronchial tumour	Left lung adenosquamous carcinoma	Cerebral oedema
23	70	Male	Orofacial cellulitis	Submandibular abscess	Septic Shock
24	71	Male	Severe anaemia in a known hypertensive diabetic with chronic kidney disease and advanced colorectal carcinoma	Perforated colorectal carcinoma	Septic Shock
25	75	Male	Gastric outlet obstruction secondary to chronic diabetes mellitus	Infiltrating gastric adenocarcinoma	Anaemic heart failure with pulmonary oedema

Table 3 Immediate cause of death established by the autopsy. Three leading causes of death were raised intracranial pressure, septic shock and pulmonary oedema.

Immediate cause of death	Number of cases (%)
Raised intracranial pressure	20 (26.67%)
Septic shock	20 (26.67%)
Pulmonary oedema	15 (20%)
Haemorrhagic shock	7 (9.33%)
Asphyxia	5 (6.67%)
Anaemic heart failure	3 (4%)
Aspiration pneumonitis	1 (1.33%)
Carcinomatosis	1 (1.33%)
Cardiogenic shock	1 (1.33%)
Hepatic failure	1 (1.33%)
Ischaemic heart disease	1 (1.33%)
Total	**75 (100%)**

Discussion

This study examined the quality of the post-mortem examination as a core component in overall patient care. This was a retrospective study aimed at verifying the extent of compliance with strict attention to details that constitute autopsy quality. The only means to conduct an assessment of quality in such a retrospective study like this was by systematically scrutinising the documentation of the autopsy findings in the authenticated and archived autopsy reports. Scordi-Bello et al in their study underscored the prime position of the autopsy in tracking major errors in antemortem clinical care which if detected could have altered the course of disease significantly[(4)]. This finding of significant errors at autopsy, some of which could have altered patient's outcome significantly was corroborated by Shojania et al in their series in which they found major error rates of 23.5%[(5)]. Komolafe et al also posited that some of the misdiagnosed conditions are common ailments and indeed treatable benign conditions[(6)]. This opinion is further strengthened by Nwafor et al in their study who opined that morbidity and mortality patterns are reflections of disease burdens[(7)]. It then means that the post-mortem examination, if properly carried out could translate to experience and

knowledge that could help in subsequent patients' care. The autopsy has no doubt over the ages played eminent roles in medical care such as confirming the working clinical diagnosis and if the clinical diagnosis is wrong, the autopsy shows convincing reasons why the diagnosis was wrong; the progression of disease, the complications, the stage of the disease at death, and may also highlight or detect medicolegal issues beforehand[8]. While our study showed a male to female ratio of 1.5:1, Nwafor et al found a male to female ratio of 1.3:1 while Komolafe et al found a male to female of 1.6:1. Both studies show a male preponderance in gender involvement in diseases. This may be due to genetic differences and sociocultural demands on males globally which makes the male gender vulnerable due to exposure to the vicissitudes of life. Pakis et al found a concordance rate of clinical and autopsy diagnoses in 49.1% while the discordance rate was 14.7%. Pakis further highlighted that ischaemic heart disease resulting in myocardial infarction, bacterial pneumonia and ruptured aortic aneurysm were the often-missed diagnoses[9]. However, Komolafe et al in their study found that the often misdiagnosed cases were systemic hypertension and the associated complications, lobar pneumonia, intracranial haemorrhage, hepatocellular carcinoma and renal cell carcinoma[8]. Baker found discordance rates in 39.7% of their autopsies. Komolafe et al had found a concordance rate of 64% compared to a discordance rate of 36% in an earlier study of medical errors discovered at autopsy that could precipitate medical litigations[6]. Loughrey et al in their study established that major discrepancies are encountered at post in 10% of cases[10]. Daramola et al found 11% of discrepancies from their study[11].

The major causes of death in this study terminally were septic shock, raised intracranial pressure, pulmonary oedema and haemorrhagic shock accounting for 26.7%, 26.7%, 20.0% and 9.3%, respectively. The leading role of infections as a leading cause of death in our findings were corroborated by Akinwusi et al who asserted from their studies that infections was a leading cause of sudden death[12]. Komolafe et al found that infections were most likely to result in death when they were missed or misdiagnosed[6]. The finding of raised intracranial pressure as a major cause of death terminally due to cerebrovascular accidents from long-standing systemic hypertension is corroborated by Akinwusi et al who found the complications of hypertension as the cause of death in 48.3% of sudden deaths as well as Komolafe et al who found that systemic hypertension were the second most common reason for misdiagnoses found at autopsy[8,13].

The Royal College of Pathologists of Australasia Autopsy Working Party stressed the role of the autopsy in patients' care and outlined the most important elements of good autopsy

practice[14]. Since the care of patients is multidisciplinary, it is therefore imperative for all health professionals to see optimum healthcare delivery as a team responsibility. The physician and nursing personnel are the closest to patients of all heath care providers. Both owe the anatomical pathologist strict documentation of antemortem events as the basis of reference for the pathologist. The role of forensic nursing personnel in counselling for the autopsy, ensuring standards and communicating findings to other nursing personnel and patients' relatives is crucial in qualitative autopsy practice[15,16]. The pathologist also owes the management team the duty of feedback from the post-mortem examination or inviting or interacting with the team to clarify grey areas and correlate morphological features with clinical presentation. The issues of quality control and assurance in autopsy pathology is a subject that warrants interminable interrogations until all hidden facts are excavated, considering the vital role the autopsy plays in patients' management[14]. Discrepancies in the concordance and discordance rates may be due to variable experiences of physicians and nursing personnel in the management team in different medical facilities across diverse nations. Missed diagnoses may be the subject of medical litigations with serious consequences for health professions in terms of integrity, finance and career. These negative consequences are well captured in the travails of healthcare professional exemplified by R v Hadiza Bawa-Garba[17]. Di Nunno et al emphasised the role of quality autopsy in ascertaining the exact cause to death, assessing the quality of care given antemortem and also excluding professional liability in malpractice suits[18].

The role of the hospital autopsy is time-honoured with veritable benefits proving that death though irreversible is not final in terms of its numerous contributions to the effectual practice of medicine[19,20]. Every patient dead or alive deserves the right diagnosis and this should be properly documented. For the dead that had post-mortem examinations performed on them; there are gains that are practical, memorable academic lessons cum experiences and sometimes theoretical that helps us to audit our practice extensively with a view to extrapolating the lessons learnt to the management of living patients so as to prevent worsening morbidity, improve the quality of life and delay mortality[21,22]. The post-mortem examination is the key to understanding with certainty the evolution of diseases and therefore brilliantly writing the disease history in retrospect, correlation of clinical features with organ structural changes, predicting the likely outcomes in the future when new cases present with similar features, staging the disease in the living and dead, effectively correlating results and reports of ancillary investigations with autopsy findings[14,23].

The contributions of the dead to knowledge and by extension the practice of medicine is seemingly endless as it includes auditing the skills and competence of all members of the management team[2,24]. This is because the findings at autopsy is used to evaluate the judgement of the medical and paramedical personnel involved in the management of the patient, documentations and decisions taken by them on the patient[25]. The autopsy is thus the reveal of undocumented secrets and ultimate arbiter where the circumstances as well as the mechanisms of death are brought to the fore. The post-mortem examination also enables us to clarify and resolve issues which arise in the course of the management of patients which have immediate and remote medicolegal importance and significance. This includes rationally, logically and systematically ruling out beyond every reasonable doubt the differential diagnoses and mimics which generated conflicts in the course of the management of the patient[19,20,26]. Post-mortem clinicopathological meetings based on autopsy findings would enable medical, nursing personnel and all that participated in the management of the patient to prepare ahead as fact witnesses, should medicolegal issues arise.

There is no doubt that the living gains immensely from the documentations of post-mortem examination which are actually products of diverse modes of experience garnered over many years. Thus, these invaluable gains of the living from the postmortem examination of the dead include understanding the aetiology and therefore the nature of disease, its evolution and pathogenesis, circumstances unique to the patient that may vary the pathogenesis and patterns of disease expression, the most likely disease outcomes, progressive stages and ultimate prognostication.

The central role of the autopsy compels us to put appropriate structures in place to properly conduct all aspects of the autopsy with professional competence and utmost excellence[27]. This then makes quality control issues in autopsy pathology highly imperative[28,29]. Items of major importance in quality control include establishing that an autopsy was indeed performed by competent personnel[30], the safety of medical personnel in the autopsy suite such as strict compliance on a routine basis with basic safety protocol[31,32], the technical approach or method of dissection, the appropriate interpretations given, flawless biodata, vital statistics of major organ-systems (measurements and weights give us the idea of the extent of deviation from normal sizes and weights), appropriate description of the organs before conclusions to the right diagnosis, provisional anatomic summary, final anatomical summary and rational cum systematic clinicopathological correlations. Unfortunately, despite the tangible benefits of the autopsy, there is an increasing worrisome decline in the number

of autopsies been performed worldwide due to diverse reasons some of which include lack of trained personnel, over-reliance on pre-mortem investigations to establish the cause of death and fear of litigations among clinicians[26,33–35].

The autopsy if properly conducted should generate moral, ethical and professional questions which the pathologist, requesting clinician and all relevant stakeholders must answer sincerely. Such questions include:

- What was the primary disease that initiated the sequence of events that culminated in the death of the patient?
- What is the cause and circumstance of patient's death?
- Were the clinical deductions compatible with the autopsy findings?
- Was the working clinical diagnosis, correct?
- Was it a misdiagnosis or missed diagnosis?
- Why was the diagnosis missed?
- What facilities for investigations are not available for proper management?
- What level of doctors and nurses managed, performed surgeries and procedures, or interpreted laboratory, radio-diagnostic and other reports?
- Could the outcome have been better in the hands of more experienced and more qualified personnel?
- Do we need re-training or more exposure for some of our staff?
- Have new equipment for investigations really helped our sense of judgment?
- Is the hospital equipment duly and periodically calibrated?
- Are personnel well trained to handle the equipment and deploy them appropriately to the needs of patients?
- Which staff is the "weak link" in the managements of cases (wards, units, clinics, surgeries, etc.)?
- Do we judge/grade our degree of errors, ascertain our culpability and seek to prevent recurrence?
- At what time do patients die most: during call duty periods, weekends when all hands may not be on deck?
- Are documentations adequate to capture the last 30 minutes of patients' lives?

- What is the benefit/added value of our continuing education, researches, updates, workshop, conferences and seminars to professional development of medical personnel?
- Has interprofessional wrangling/rivalry not severely compromised patients' care?
- Are there not communication lapses between aggrieved health practitioners?
- Have health workers not abandoned patients' and public interests for research?
- What seeds of professional excellence are systematically sown for the future of the individual professions and corporate practice?
- Do researches really enable evidenced-based medical practice?
- Should there be budgetary modifications to meet present needs and realities?

An autopsy service of acceptable quality should meet the needs of the requesting clinicians, address the problems faced by the health professionals in the management of every case, contribute to the improvement of patient care, answer the questions of relatives of the deceased as best as possible, meet legal requirements as well as ensure the highest standards of practice and safety of the pathologist[36].

Conclusion

Though assessing quality in a multistage exercise like the autopsy may be challenging, a stepwise approach would help in ensuring that quality is maintained in the post-mortem examination. The meticulous attention to details will ensure that this unique clinical care gold standard tool itself indeed remains unassailable and continues to stand out as the veritable assessor that it is meant to be. The autopsy presents the best means of clinicopathologic assessment as it correlates the autopsy findings and clinical diagnoses. Good communication between the pathologists, clinicians, nurses and all health personnel involved in patients' care is advocated on a consistent basis so as to improve care for future patients and for the overall benefit of the healthcare system. Despite the exuberant over-hyping of modern diagnostic techniques and their seeming invincibility claims to detect and diagnose every disease, the autopsy remains the best available forensic tool and its conduct requires the highest possible quality standards.

References

(1). Croft P, Altman DG, Deeks JJ, Dunn KM, Hay AD, Hemingway H, et al. The science of clinical practice: Disease diagnosis or patient prognosis? Evidence about 'what is likely to happen' should shape clinical practice. BMC Med. 2015;13(1):1–8.

(2). EM C. Nurses, Negligence and Malpractice. Am J Nurs. 2003;103(9):54–63.

(3). Kuijpers CCHJ, Fronczek J, Van De Goot FRW, Niessen HWM, Van Diest PJ, Jiwa M. The value of autopsies in the era of high-tech medicine: Discrepant findings persist. J Clin Pathol. 2014;67(6):512–9.

(4). Tette E, Yawson AE, Tettey Y. Clinical utility and impact of autopsies on clinical practice among doctors in a large teaching hospital in Ghana. Glob Health Action. 2014;7(1):1–7.

(5). Komolafe AO. The Morphological Basis and Laws of Autopsy Interpretation: Exploring the Relationship between the Basic Medical Sciences, Anatomical Pathology and Clinical Practice. In: Sheriff D.S., editor. Current Trends in Medicine and Medical Research Vol 4. 4th ed. West Bengal: Book Publisher International; 2019. p. 74–9.

(6). Scordi-Bello IA, Kalb TH, Lento PA. Clinical setting and extent of premortem evaluation do not predict autopsy discrepancy rates. Mod Pathol. 2010;23(9):1225–30.

(7). Shojania KG; Burton EC; McDonald KM; Goldman L. Changes in rates of autopsy-detected diagnostic errors over time: a systematic review. JAMA – J Am Med Assoc. 2003;289(21):2849–56.

(8). Komolafe AO, Adefidipe AA, Akinyemi HAM, Ogunrinde O V. Medical Errors Detected at the Autopsy: A Prelude to Avoiding Malpractice Litigations. J Adv Med Med Res. 2018;27(7):1–8.

(9). Nwafor CC, Nnoli MA CC. Causes and pattern of death in a tertiary hospital in Southeastern Nigeria. Sahel Med J. 2014;17(3):102–7.

(10). Komolafe AO, Adefidipe AA AH. Correlation of antemortem diagnoses and postmortem diagnoses in a preliminary survey - any discrepancies? Niger J Fam Pract. 2018;9(1):105–8.

(11). Pakis I, Polat O, Yayci N, Karapirli M. Comparison of the Clinical Diagnosis and Subsequent Autopsy Findings in Medical Malpractice. Am J Forensic Med Pathol. 2010;31(3):218–21.

(12). Loughrey M, McCluggage W. The declining autopsy rate and clinicians' attitudes. Ulster Med J. 2000;69(2):83–9.

(13). Daramola AO, Elesha SO, Banjo AAF. Medical audit of maternal deaths in the Lagos University Teaching Hospital, Nigeria. East Afr Med J. 2005;82(6):285–9.

(14). Akinwusi PO, Komolafe AO, Olayemi OO, Adeomi AA. Communicable disease-related sudden death in the 21st century in Nigeria. Infect Drug Resist. 2013;6(6):125–32.

(15). Akinwusi PO, Komolafe AO, Olayemi OO, Adeomi AA. Pattern of sudden death at Ladoke Akintola university of technology teaching hospital, Osogbo, South West Nigeria. Vasc Health Risk Manag. 2013;9(1):333–9.

(16). Davies DJ, Graves DJ, Landgren AJ, Lawrence CH, Lipsett J, MacGregor DP, et al. The decline of the hospital autopsy: A safety and quality issue for healthcare in Australia. Vol. 180, Medical Journal of Australia. 2004. p. 281–5.

(17). Gorea R. Role of Forensic Nurses in the mortuary and postmortem examination. Int J Ethics, Trauma Vict. 2020;6(01):6–9.

(18). Maixenchs M, Anselmo R, Sanz A, Castillo P, Macete E, Carrilho C, et al. Healthcare providers' views and perceptions on post-mortem procedures for cause of death determination in Southern Mozambique. PLoS One. 2018;13(7):1–16.

(19). Bawa-Garba H. EWCA Criminal (2016). 1841.

(20). Di Nunno N, Patanè FG, Amico F, Asmundo A, Pomara C. The Role of a Good Quality Autopsy in Pediatric Malpractice Claim: A Case Report of an Unexpected Death in an Undiagnosed Thymoma. Front Pediatr. 2020;8(February):4–8.

(21). Akinwumi Oluwole Komolafe NAT. Autopsy Pathology: General Principles and Interpretation. Niger Clin Rev J. 2008;71(2):31–3.

(22). Komolafe A.O.; Titiloye N.A. Essentials of Autopsy Pathology. Niger J Fam Pract. 2016;7(1):7–14.

(23). Adeniran AA, Adegoke OO, Komolafe AO. Cardiac tamponade complicating thoracocentesis: A case for image-guided procedure. Pan Afr Med J. 2018;29.

(24). Burton JL, Underwood J. Clinical, educational, and epidemiological value of autopsy. Vol. 369, Lancet. Elsevier; 2007. p. 1471–80.

(25). Goldman L, Sayson R, Robbins S, Cohn LH, Bettmann M, Weisberg M. The Value of the Autopsy in Three Medical Eras. N Engl J Med. 1983;308(17):1000–5.

(26). Lewis G. Reviewing maternal deaths to make pregnancy safer. Best Pract Res Clin Obstet Gynaecol. 2008;22(3):447–63.

(27). De Vlieger GYA, Mahieu EMJL, Meersseman W. Clinical review: What is the role for autopsy in the ICU? Vol. 14, Critical Care. 2010.

(28). Komolafe A.O.; Titiloye N.A. The role of the pathologist in medical litigations. Niger J Postgrad Med. 2009;2(1):18–25.

(29). Schröder AS, Wilmes S, Sehner S, Ehrhardt M, Kaduszkiewicz H, Anders S. Post-mortem external examination: competence, education and accuracy of general practitioners in a metropolitan area. Int J Legal Med. 2017;131(6):1701–6.

(30). Guly HR. Diagnostic errors in an accident and emergency department. Emerg Med J. 2001;18(4):263–9.

(31). van den Tweel JG, Wittekind C. The medical autopsy as quality assurance tool in clinical medicine: dreams and realities. Virchows Arch. 2016;468(1):75–81.

(32). Adeyi OA. Pathology Services in Developing Countries — The West African Experience. Arch Pathol Lab Med. 2011;135(2):183–6.

(33). Sharma BR, Reader MD. Autopsy Room: A Potential Source of Infection at Work Place in Developing Countries. Am J Infect Dis. 2005;1(1):25–33.

(34). Croner. Health and Safety at Work. J Clin Pathol. 1998;36:254–60.

(35). David M. Studdert MMM, Atul A. Gawande TKG, Allen Kachalia CY, and Troyen A. Brennan ALP. Claims, errors, and compensation payments in medical malpractice litigation. N Engl J Med. 2006;354(19):2024–33.

(36). Blendon RJ, DesRoches CM, Brodie M, Benson JM, Rosen AB, Schneider E, et al. Views of Practicing Physicians and the Public on Medical Errors. N Engl J Med. 2002;347(24):1933–40.

CASE REPORT

Matrix producing clear cell primary pulmonary myoepithelial carcinoma: a case report with a review of the literature

Gittwa Vatsaraj Kottangal*, Shalini Kuruvila and Kavitha Kanjirakkattumana Parameswaran

Department of Pathology, Aster MIMS, Kozhikode, Kerala, India

* Correspondence to: Dr Gittwa Vatsaraj Kottangal, Department of Pathology, Aster MIMS, Kozhikode, Kerala 673016 India. Telephone: 009 170 259 552 93 Email: drgitwa@hotmail.com

Conflict of interest: The authors declare that they have no conflicts of interest with the contents of this article.

Submitted: *11 April 2021*
Accepted: *21 April 2021*
Published: *1 January 2021*

Abstract

Myoepithelial carcinoma, also known as malignant myoepithelioma, is mainly encountered in the salivary glands and, at a lower incidence, in the sweat glands (skin), breast, soft tissue, bone and very rarely in the lung. Pulmonary myoepithelial carcinoma was first described by Higashiyama et al. in 1998, and to the best of our knowledge, only 15 cases have been reported in the English literature so far. The reports are that of 13 adults and 2 paediatric cases. Herein we report a case of a matrix producing clear cell primary pulmonary myoepithelial carcinoma in a 64-year-old male patient who presented with chronic cough and respiratory distress. The characteristic histomorphological and the immunohistochemical features of the tumour were used to further discuss the distinct clinicopathologic features, differential diagnosis, treatment and prognosis of the entity.

Keywords: histomorphology; immunohistochemistry; matrix; myoepithelial; pulmonary

Introduction

Myoepithelial carcinoma of the lung is a rare neoplasm, accounting for 0.1 – 0.2% of all lung tumours. This tumour arises from the submucosal bronchial glands, which are considered to be minor salivary glands. The various benign and malignant salivary gland type tumours of the lung include mucoepidermoid carcinoma, adenoid cystic carcinoma, epithelial-myoepithelial carcinoma, pleomorphic adenoma, acinic cell carcinoma, oncocytoma, myoepithelioma and myoepithelial carcinoma. Considering the lack of ductal/glandular differentiation, 2015 World Health Organization (WHO) classification of lung tumours enclosed myoepithelial carcinoma as a new separate entity differentiating it from epithelial-myoepithelial carcinoma and pleomorphic adenoma. Ultrastructurally, myoepithelial cells show both epithelial and smooth muscle differentiation features, with myofilaments, tonofilaments, desmosomes and external lamina. This differentiation is the reason for the varying histological morphology of the myoepithelial tumours. This report describes the case of a 64-year-old male patient with primary myoepithelial carcinoma of the lung with clear cell morphology.

Case Report

A 64-year-old non-smoking man presented in the Department of Pulmonology with non-productive chronic cough and dyspnoea of 4 months duration. A chest X-ray revealed mass lesion. Positron emission tomography – computed tomography (PET-CT) showed abnormally increased tracer uptake in enhancing peripheral areas of a thick-walled cavitary lesion (measuring 6.0 x 5.4 x 5.7 cm) in the superior segment of the lower lobe of the left lung, extending to hilum (*Figure 1*). Additionally, there was a nodular soft tissue density lesion (measuring 2.8 x 2.4 cm) with lobulated margins in the anterior segment of the upper lobe of the left lung (*Figure 2*) and metabolically active discrete mediastinal lymph nodes, i.e. left lower paratracheal, left hilar, subaortic and left peribronchial lymph nodes (*Figure 1*).

Computed tomography (CT) – guided fine needle aspiration cytology (FNAC) and Tru-Cut biopsy were taken from the soft tissue density lesion in the anterior segment of the left lung upper lobe. FNAC smear was of low cellularity, showing poorly cohesive clusters of malignant cells with mildly pleomorphic hyperchromatic nuclei and a moderate amount of pale eosinophilic to clear cytoplasm. The background showed pale eosinophilic material (*Figure 3*). Tru-Cut biopsy showed lung tissue infiltrated by a neoplasm composed of cells with hyperchromatic nuclei and a moderate amount of pale eosinophilic to clear cytoplasm

arranged as cords, nests and fused glands in blobs of an acellular pale eosinophilic matrix. Comedo necrosis and 12 – 13 mitoses per 10 high-power fields (HPFs) were seen (*Figures 4A and 4B*).

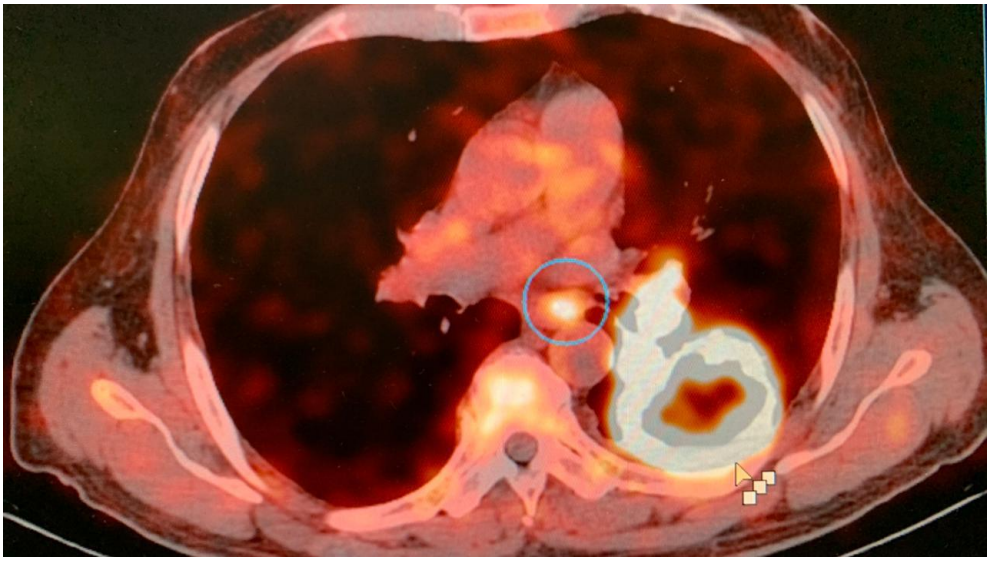

Figure 1 Positron emission tomography – computed tomography (PET-CT) of the chest. There was abnormally increased tracer uptake in enhancing peripheral areas of a thick-walled cavitary lesion in the superior segment of the lower lobe of the left lung, extending to the hilum (*white arrow*) and metabolically active discrete mediastinal lymph nodes (*blue circle*).

Immunohistochemistry showed diffusely strong positivity for p63 (*Figure 5*) and moderate positivity for S100 (*Figure 6*). There was negative immunoexpression for CD10, CD117, CK7, HMB-45, synaptophysin and TTF1. With the above histomorphological and immunohistochemical features, the diagnosis of primary myoepithelial carcinoma of the lung, clear cell type was given. Due to poor health conditions, surgery was not done, and the patient was put on chemotherapy. For 9 months, the patient shows no progression of the disease and is alive with the disease.

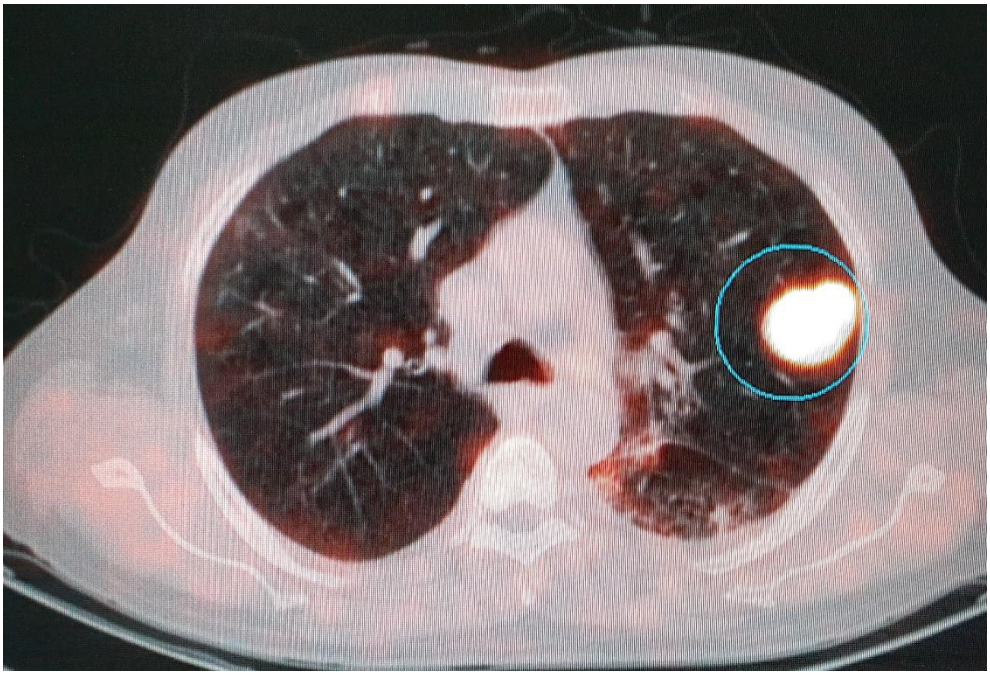

Figure 2 Positron emission tomography – computed tomography (PET-CT) of the chest. There was nodular soft tissue density lesion with lobulated margins in the anterior segment of the upper lobe of the left lung (*blue circle*).

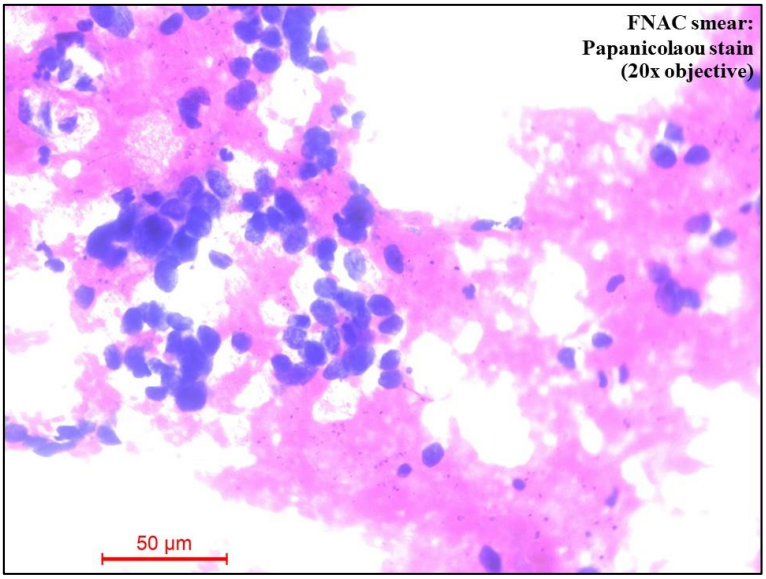

Figure 3 Fine needle aspiration cytology (FNAC) smear of the lung mass [*Papanicolaou (PAP) Stain, 20x objective*]. There were poorly cohesive clusters of malignant cells with mildly pleomorphic hyperchromatic nuclei and a moderate amount of pale eosinophilic to clear cytoplasm. The background showed pale eosinophilic material.

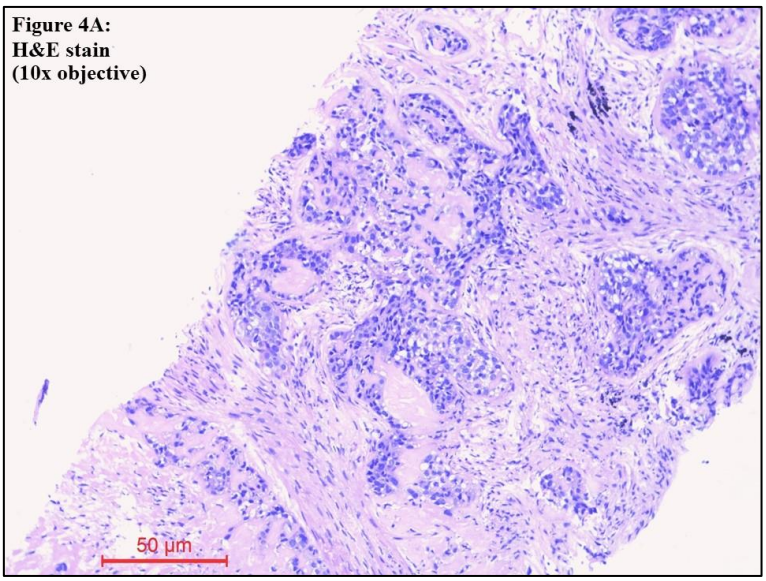

(A). 10x objective

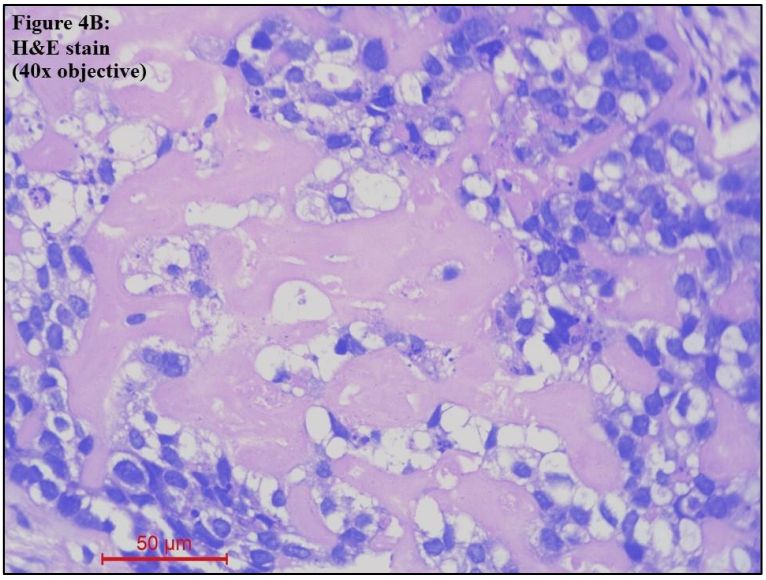

(B). 40x objective

Figure 4 Lung tissue obtained from Tru-Cut biopsy [*haematoxylin and eosin (H&E) stain*]. (A). The lung tissue was infiltrated by a neoplasm arranged as cords, nests and fused glands in blobs of an acellular pale eosinophilic matrix (*10x objective*). **(B).** The cells had moderately pleomorphic hyperchromatic nuclei and a moderate amount of pale eosinophilic to clear cytoplasm (*40x objective*).

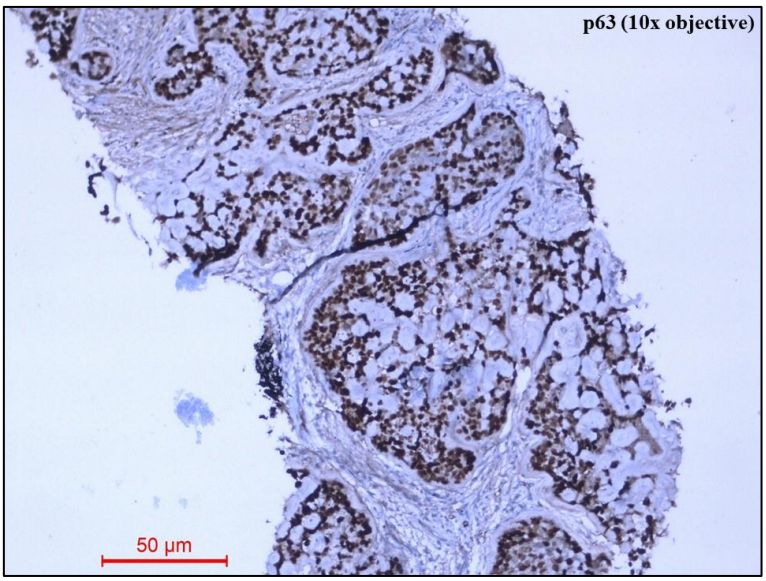

Figure 5 Immunohistochemistry of p63 protein (*10x objective*). The tumour cells showed diffusely strong nuclear immunostaining of p63.

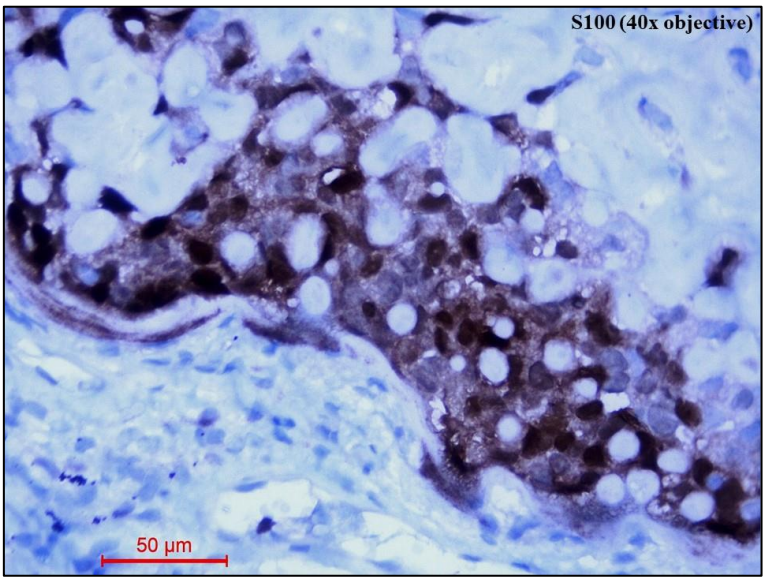

Figure 6 Immunohistochemistry of S100 protein (*40x objective*). The tumour cells showed both nuclear and cytoplasmic immunostaining of S100.

Discussion

In 1943, Sheldon identified myoepithelial tumours as a distinct entity in salivary glands[1], while the malignant counterpart — myoepithelial carcinoma — was first described by Stromeyer et al. in salivary glands in 1975[2]. In 1987, Strickler et al. reported the first case of a benign myoepithelioma in the lung[3]. While primary pulmonary myoepithelial carcinoma is first described by Higashiyama et al. in 1998[4]. Myoepithelial tumours were recognised as a histologically distinct entity by the WHO in 1991 in salivary gland tumours[5]. While myoepithelial tumours/carcinomas entered as a separate entity in the 2015 WHO classification of lung tumours[6]. Primary salivary gland – type lung tumours are very rare and represent less than 1% of all lung tumours[7,8]. Pulmonary primary myoepithelial carcinoma is even rare, encountering only 0.1 – 0.2% of all lung tumours.

To the best of our knowledge, only 15 cases of primary pulmonary myoepithelial carcinoma have been reported in the English literature[9]. The clinical data of these reported cases are shown in the *Table*. Adult cases range in age from 24 to 76 years old (mean age of 55.5 years) and paediatric cases are that of 7- and 13-year-old girls. The male-to-female ratio is 7:8. Six out of 16 cases have a history of smoking. Five cases presented as endobronchial mass and 11 cases had peripheral mass. Except 2 cases, all underwent resection. Six cases had metastasis. One case had a recurrence. Seven cases were alive without disease. Five cases were alive with disease. Two cases died of the disease. One case died due to other cause. However, two cases had unavailable follow-up data.

Myoepithelial cells are seen in the secretory organs like salivary glands, breast, sweat gland, prostate, etc. These cells surround acini and intercalated ducts and express a dual epithelial and smooth muscle phenotype. They are thought to be ectodermal in origin[1]. The neoplastic behaviour of these cells is at times unpredictable and forms either a major component of the myoepithelial entities (like myoepithelioma and myoepithelial carcinoma) or as one of the components of the tumours like epithelial, myoepithelial carcinoma, pleomorphic adenoma and adenoid cystic carcinomas[4].

Table The clinical data of fifteen reported cases of primary pulmonary myoepithelial carcinoma.

Case	Age (Years old)	Gender	Smoking	Tumour location	Tumour size (cm)	Treatment	Metastasis	Survival	Reference
1	58	Male	Yes	Right upper lung, Endobronchial	3.8	Sleeve lobectomy	Forearm and hip muscles	14 months (Died of other cause)	Higashiyama et al.[4]
2	58	Male	Yes	Left upper lung, Endobronchial	6.0	Sleeve lobectomy	liver	60 months (Died of the disease)	Higashiyama et al.[4]
3	No data	No data	No data	No data	No data	No data	Yes	No data	Sekine et al.[13]
4	46	Male	No data	Endobronchial	6.5	Right pneumectomy	Left lower lung	7 months (Alive with the disease)	Miura et al.[14]
5	48	Male	Yes	Left lower lung, Peripheral	1.5	Resection	None	15 months (Alive without the disease)	Masuya et al.[15]
6	76	Male	Yes	Left lower lung, Peripheral	2.2	Wedge resection	Brain	11 months (Died of the disease)	Tanahashi et al.[16]
7	63	Female	No	Right lower lung, Pleural, Peripheral	13	Resection	Liver and diaphragm	36 months (Alive with the disease)	Sarkaria et al.[17]
8	65	Female	No	Left lower lung, Peripheral	2.5	Resection of the right and left lower lungs	Right lower lung	10 months (Alive without the disease)	Hysi et al.[18]
9	72	Female	Yes	Right upper lung, Endobronchial	1.5	Wedge resection	None	7 months (Alive without the disease)	Rosen et al.[19]
10	47	Male	Yes	Left lower lung, Peripheral	6.5	Resection	None	6 months (Alive without the disease)	Wei et al.[20]
11	51	Female	No data	Right lower lung, Peripheral	2.0	Wedge resection	None	36 months (Alive without the disease)	Zhang et al.[21]
12	24	Female	No	Left upper lung, Peripheral	5.0	Resection	None	12 months (Alive without the disease)	Zhou et al.[22]
13	13	Female	No	Both lungs, Peripheral	6.3 and 7.4	Inoperable	None	Lost follow-up	Kridis et al.[23]
14	7	Female	No	Left upper lung, Endobronchial	7.0	Pneumectomy and radiotherapy	None	14 months (Alive without the disease)	Filisetti et al.[9]
15	45	Female	No	Right lower lung, Peripheral	3.5	Lobectomy and chemotherapy	Recurrence	12 months (Alive with the disease)	Yoshida et al.[12]

Myoepithelial carcinoma in the lung presents as either an endobronchial mass or a peripheral mass. The tumour develops from both the central and the peripheral bronchial glands. Grossly, the tumour is usually well-circumscribed, ranging from 1.5 to 20 cm, with a yellow-tan, sometimes glistering cut surface[6,10]. Myoepithelial carcinoma is a malignant tumour that is entirely composed of myoepithelial cells with variable cellular morphologies, including spindle (most common), epithelioid, plasmacytoid, or clear cells (least common) along with a variable stromal component. It can be differentiated from myoepithelioma by the following criteria, i.e nuclear atypia, multinucleation, prominent nucleoli, high mitotic rate (an average of 13 mitoses per 10 HPFs) and necrosis. The tumour cells express epithelial markers (EMA and pan-CK) and at least one myoepithelial marker [caldesmon, calponin, glial fibrillary acid protein (GFAP), p40/p63, S100 and smooth muscle actin (SMA)][10]. They will be negative immunostainings for CK7 (showing the absence of epithelial/glandular differentiation) and TTF1[6].

Frequent *EWSR1* and *FUS* rearrangements[11] and case reports with *SMARCB1* loss[12] are also seen. It is seen that specific histomorphological findings can be related to specific gene fusion products. Tumours with *EWSR-PBX1* fusion were characterised by spindle cell proliferation with clear cytoplasm, while *EWSR-ZNF444* translocation is seen in the epithelioid type of tumour cells. In a few cases with clear cell morphology, no specific fusion partners for *EWSR* were detected[11]. *SMARCB1* loss is found in the case with rhabdoid morphology[12].

Treatment for myoepithelial carcinoma is surgical resection. Unfavourable cases are also treated with chemotherapy and radiotherapy[12]. Since the reported cases on this entity are very few, the knowledge regarding treatment is also limited. This tumour can metastasise to brain, contralateral lung, liver and soft tissue. A lower mitotic count is a favourable prognostic factor of clinical outcome and survival in primary myoepithelial carcinoma of the lung[6].

The differential diagnosis for the lung tumours with clear cell morphology includes PECOMA (clear cell/sugar tumour), hyalinising clear cell carcinoma, clear cell adenocarcinoma, clear cell variant of squamous cell carcinoma, epithelial myoepithelial carcinoma and metastatic clear cell carcinoma.

1. ***PECOMA (clear cell/sugar tumour)***

   This tumour consists of round or oval clear cells with abundant glycogen containing cytoplasm, which shows strong diastase-sensitive PAS positivity. Nucleoli may be prominent. Stroma is scanty with prominent thin-walled sinusoidal vessels. Mitosis and necrosis are extremely rare. Malignancy should

be suspected if the tumour is infiltrative or shows significant mitotic activity. Immunohistochemistry shows positive for HMB-45 and S100. There is negative immunoexpression for pan-cytokeratin cocktail AE1/AE3, CK7, CK20 and p63/p40[24].

2. ***Hyalinising clear cell carcinoma***

These tumours are of salivary gland origin. The tumour cells form sheets, nests, and cords. No definite glandular formation is seen. Stroma has thick parallel strands of fibrous tissue associated with the hyalinised and myxoid substance. Cells are polygonal to round with abundant pale eosinophilic to clear cytoplasm, bland nuclei with fine chromatin, small or inconspicuous nucleoli[25]. Some cells show intranuclear pseudoinclusions, usually no necrosis, nuclear pleomorphism, or increase in mitosis. The periphery of the tumour shows chronic inflammatory infiltrate. Immunohistochemistry shows positivity for pan-keratin, CK7 and p63. Cells are negative for CD10, CK20, chromogranin, synaptophysin, HMB-45, napsin A, PAX-8 and TTF-1, and consistently negative for the myoepithelial markers like S-100, SMA and calponin. Molecular testing shows EWSR1-ATF1 fusion, which is also seen in clear cell sarcoma of soft tissue and angiomatoid fibrous histiocytoma[26].

3. ***Clear cell adenocarcinoma***

The tumour shows predominantly clear cells arranged in glandular and papillary patterns. The cells are columnar and cuboidal with a moderate amount of clear cytoplasm, nuclear stratification seen with hyperchromatic nuclei, and small prominent nucleoli. Mitosis is seen. Special stains show no glycogen or mucins in the cytoplasm. Immunohistochemically, the tumour cells are positive for pan-cytokeratin, CK7, CK8, CK18, CK19, CEA, CA19-9, CA125, EMA, p53, surfactant apoprotein A and TTF-1. The tumour cells are negative for AFP, CD10, CK5/6, CK14, CK20, CK34βE12, HMB45, p63, S100, SMA, synaptophysin and vimentin[27].

4. ***Clear cell variant of squamous cell carcinoma***

Squamous cell carcinomas are tumours characterised by keratinisation and/or intercellular bridges. They arise from bronchial epithelial cells through squamous metaplasia/dysplasia. The 2004 WHO classification had 4 variants of squamous cell carcinoma, i.e. clear cell, small cell, papillary and basaloid[28].

The 2015 WHO classification had no longer recommendation on this classification[10]. Clear cell is considered to be more of a cellular change than a pattern and can occur in all histological categories of squamous cells. Immunohistochemistry shows positivity for CK5/6, p40 and p63, and negative for calponin, CK7, CK20, other myoepithelial markers like S100, SMA and TTF1[28].

5. ***Epithelial myoepithelial carcinoma***

   The tumour shows dual cell types, i.e. the duct/gland forming epithelial cells and the outer layer of myoepithelial cells. The epithelial cells are positive for CK7, while the myoepithelial cells are positive for CK5/6, p63, S100 and SMA[29].

6. ***Metastatic clear cell carcinoma***

   This tumour reveals specific histomorphology and immunohistochemical markers for their cells of origin[12].

Conclusion

In conclusion, clear cells and matrix-producing lung tumours should raise the suspicion of myoepithelial carcinoma. Since the available data regarding this rare entity is very minimum, big data case studies have to be undertaken for better treatment modalities and outcome of the disease.

Acknowledgement

This case report would not have been possible unless we were supported by the Departments of Nuclear Medicine, of Radiology and of Pathology at Aster MIMS, Kozhikode, Kerala, India and Dr Ajith Bhaskar, a pulmonologist in Kozhikode, Kerala, India.

References

(1). Sheldon WH. So-called mixed tumors of the salivary glands. Arch Pathol. 1943;35:1–20.

(2). Stromeyer FW, Haggitt RC, Nelson JF, Hardman JM. Myoepithelioma of minor salivary gland origin. Light and electron microscopical study. Arch Pathol. 1975;99:242–5.

(3). Strickler JG, Hegstrom J, Thomas MJ, Yousem SA. Myoepithelioma of the lung. Arch Pathol Lab Med. 1987;111:1082–5.

(4). Higashiyama M, Kodama K, Yokouchi H, et al., Myoepithelioma of the lung: report of two cases and review of the literature. Lung Cancer. 1998;20:47–56.

(5). Seifert G, Sobin LH. Myoepithelioma. World Health Organization International Histological Classification of Tumours: Histological Typing of Salivary Gland Tumours. 2nd ed. Berlin, Germany: Springer-Verlag; 1991. pp. 20-1.

(6). Travis WD, Brambilla E, Burke AP, Marx A, Nicholson AG. WHO Classification of Tumours of the Lung, Pleura, Thymus and Heart. International Agency for Research on Cancer, Lyon: 2015.

(7). Zhu F, Liu Z, Hou Y, et al. Primary salivary gland-type lung cancer: clinicopathological analysis of 88 cases from China. J Thorac Oncol 2013;8:1578–84.

(8). Shen C, Wang X, Che G. A rare case of primary peripheral epithelial myoepithelial carcinoma of the lung: case report and literature review. Medicine (Baltimore) 2016;95:e4371.

(9). Filisetti C, Russo T, Pansini A, Vella C, Viglio C, Riccipetitoni G. The First Reported Pediatric Case of Primary Myoepithelial Carcinoma Involving the Whole Lung: Surgical Radical Treatment and Prosthesis Implant. European J Pediatr Surg Rep. 2020;8(1):e52-e55.

(10). Mengoli MC, Longo FR, Fraggetta F, Cavazza A, Dubini A, Alì G, Guddo F, Gilioli E, Bogina G, Nannini N, Barbisan F, De Rosa N, Falconieri G, Rossi G, Graziano P. The 2015 World Health Organization Classification of lung tumors: new entities since the 2004 Classification. Pathologica. 2018;110(1):39-67.

(11). Khazeni K, LaBove H, Wilky B, et al., Myoepithelial carcinoma or epithelioid sarcoma – A rare diagnosis with poor prognosis. A case report and review of literature, Int J Surg Case Rep. 2018;49:239–243.

(12). Yoshida M, Yamashita D, Hamakawa H, Takahashi Y, Yasui H, Komatsu M, Ohbayashi C, Hara S. SMARCB1-deficient myoepithelial carcinoma of the lung: A case report. Human Pathology: Case Reports, Vol 21,2020:200414.

(13). Sekine I, Kodama T, Yokose T, et al. Rare pulmonary tumors—a review of 32 cases. Oncology 1998;55:431–4.

(14). Miura K, Harada H, Aiba S, et al. Myoepithelial carcinoma of the lung arising from bronchial submucosa. Am J Surg Pathol. 2000;24:1300–1304.

(15). Masuya D, Haba R, Huang C, Yokomise H. Myoepithelial carcinoma of the lung. Eur J Cardiothorac Surg. 2005;28:775–777.

(16). Tanahashi J, Kashima K, Daa T, et al. Pulmonary myoepithelial carcinoma resembling matrix-producing carcinoma of the breast: case report and review of the literature. APMIS. 2010;118:401–406.

(17). Sarkaria IS, DeLair D, Travis WD, et al. Primary myoepithelial carcinoma of the lung: a rare entity treated with parenchymal sparing resection. J Cardiothorac Surg. 2011;6:27.

(18). Hysi I, Wattez H, Benhamed L, et al. Primary pulmonary myoepithelial carcinoma. Interact Cardiovasc. Thorac Surg. 2011;13:226–228.

(19). Rosen LE, Singh RI, Vercillo M, et al. Myoepithelial carcinoma of the lung: a review. Appl Immunohistochem Mol Morphol. 2015;23:397–401.

(20). Wei J, Yuan X, Yao Y, et al. Primary myoepithelial carcinoma of the lung: a case report and review of literature. Int J Clin Exp Pathol. 2015;8:2111–2116.

(21). Zhang Y, Li B, Hou J, et al. Primary myoepithelial carcinoma of the lung and 18F-FDG PET/CT. Rev Esp Med Nucl Imagen Mol. 2018;37:175–177.

(22). Zhou X, Yu M, Zhuo H, Zhang S. Primary pulmonary myoepithelial carcinoma in a young woman. Medicine (Baltimore). 2018;97(9):e0049.

(23). Kridis WB, Toumi N, Khanfir A, Hachicha M, Boudawara T, Frikha M. Primary pulmonary myoepithelial carcinoma in a child: An ambiguous entity. Lung India. 2015;32:497-9.

(24). Tsilimigras DI, Bakopoulos A, Ntanasis-Stathopoulos I, et al. Clear cell "sugar tumor" of the lung: Diagnostic features of a rare pulmonary tumor. Respir Med Case Rep. 2017;23:52-54.

(25). Weinreb I. Hyalinizing clear cell carcinoma of the salivary gland: a review and update. Head Neck Pathol. 2013;7:S20-S29.

(26). Jeffus SK, Gardner JM, Steliga MA, Shah AA, Stelow EB, Arnaoutakis K. Hyalinizing clear cell carcinoma of the lung: case report and review of the literature. Am J Clin Pathol. 2017;148(1):73-80.

(27). Goto T, Hada M, Oyama T. Lung adenocarcinoma with clear cell features producing carbohydrate antigen 19-9. Asian Cardiovascular and Thoracic Annals. 2015;23(8):985-987.

(28). Perez-Moreno P, Brambilla E, Thomas R, Soria JC. Squamous cell carcinoma of the lung: molecular subtypes and therapeutic opportunities. Clin Cancer Res. 2012;18(9):2443-51.

(29). Arif F, Wu S, Andaz S, Fox S. Primary epithelial myoepithelial carcinoma of the lung, reporting of a rare entity, its molecular histogenesis, and review of the literature. Case Rep Pathol. 2012;2012:319434.

APPENDIX 1
INFORMATION FOR AUTHORS

All authors listed in a paper submitted to Asian Archives of Pathology (AAP) must have contributed substantially to the work. It is the corresponding author who takes responsibility for obtaining permission from all co-authors for the submission. When submitting the paper, the corresponding author is encouraged to indicate the specific contributions of all authors (the author statement, with signatures from all authors and percentage of each contribution can be accepted). Examples of contributions include: designed research, performed research, contributed vital new reagents or analytical tools, analysed data, and wrote the paper. An author may list more than one type of contribution, and more than one author may have contributed to the same aspect of the work.

Authors should take care to exclude overlap and duplication in papers dealing with related materials. See also paragraph on Redundant or Duplicate Publication in "Uniform Requirements for Manuscripts Submitted to Biomedical Journals" at http://www.icmje.org/index.html.

The submitted manuscripts will be reviewed by three members of the Editorial Board or three expert reviewers from different institutions. At the discretion of the Editorial Board, the manuscripts may be returned immediately without full review, if deemed not competitive or outside the realm of interests of the majority of the readership of the Journal. The decision (reject, invite revision, and accept) letter will be coming from the Editorial Board who has assumed responsibility for the manuscript's review. The editor's decision is based not just on technical merit of the work, but also on other factors such as the priority for publication and the relevance to the Journal's general readership. All papers are judged in relation to other submissions currently under consideration.

Categories of Manuscripts

1. **Letters to the Editor**

   The letters to the editor are the reactions to any papers published in AAP. These letters will be reviewed by the Editorial Board and sent to the authors of the original paper with an invitation to respond. Letters and eventual responses will be published together, when appropriate.

- *Word Count: 300 – 500 words (excluding references and figure or table legends)*
- *Abstract: Not required*
- *References: Maximum of 10*
- *Figure or Table: Maximum of 1 (if needed)*

2. Original Articles

The original articles are the researches describing the novel understanding of anatomical pathology, clinical pathology (laboratory medicine), forensic medicine (legal medicine or medical jurisprudence), molecular medicine or pathobiology. Systematic reviews, meta-analyses and clinical trials are classified as articles. The articles should be clearly and concisely written in the well-organised form (see ***Organisation of Manuscripts***): abstract; introduction; materials and methods; results; discussion; and conclusions. The manuscripts that have passed an initial screening by the Editorial Board will be reviewed by two or more experts in the field.

- *Word Count: 3,000 – 5,000 words (excluding abstract, references, and figure or table legends)*
- *Structured Abstract (see* ***Organisation of Manuscripts****): 150 – 200 words*
- *References: Maximum of 150*
- *Figures or Tables: Maximum of 6*

3. Review Articles

The review articles are generally invited by the Editor-in-Chief. They should focus on a topic of broad scientific interest and on recent advances. These articles are peer-reviewed before the final decision to accept or reject the manuscript for publication. Therefore, revisions may be required.

- *Word Count: 3,000 – 5,000 words (excluding abstract, references, and figure or table legends)*
- *Unstructured Abstract: 150 – 200 words*
- *References: Maximum of 150*
- *Figures or Tables: Maximum of 4*

4. Case Reports

AAP limits publication of case reports to those that are truly novel, unexpected or unusual, provide new information about anatomical pathology, clinical pathology (laboratory medicine) or forensic medicine (legal medicine or medical jurisprudence). In addition, they must have educational value for the aforementioned fields. The journal will not consider case reports describing preventive or therapeutic interventions, as these generally require stronger evidence. Case reports that involve a substantial literature review should be submitted as a review article. The submitted case reports will undergo the usual peer-reviewed process.

- *Word Count: 1,200 – 2,000 words (excluding abstract, references, and figure or table legends)*
- *Unstructured Abstract: 150 – 200 words*
- *References: Maximum of 20*
- *Figures or Tables: Maximum of 4*

5. Case Illustrations

Case illustrations are aimed to provide education to readers through multidisciplinary clinicopathological discussions of interesting cases. The manuscript consists of a clinical presentation or description, laboratory investigations, discussion, final diagnosis, and up to 5 take-home messages (learning points). Regarding continuous learning through self-assessment, each of the case illustrations will contain 3 – 5 multiple choice questions (MCQs) with 4 – 5 suggested answers for each question. These MCQs are placed after the final diagnosis and the correct answers should be revealed after the references. The questions and take-home messages (learning points) are included in the total word count. The manuscripts that have passed an initial screening by the Editorial Board will be reviewed by two experts in the field.

- *Word Count: 1,000 – 2,000 words (excluding references and figure or table legends)*
- *Abstract: Not required*
- *References: Maximum of 10*
- *Figures: Maximum of 2*
- *Tables: Maximum of 5*

6. Technical Notes

The technical notes are brief descriptions of scientific techniques used in the anatomical pathology, clinical pathology (laboratory medicine), forensic medicine (legal medicine or medical jurisprudence), molecular medicine or pathobiology. The submitted manuscripts are usually peer-reviewed.

- *Word Count: Maximum of 1,000 words (excluding references and figure or table legends)*
- *Abstract: Not required*
- *References: Maximum of 5*
- *Figures or Tables: Maximum of 2*

Organisation of Manuscripts

1. General Format

The manuscripts written in English language are preferable. However, Thai papers are also acceptable, but their title pages, abstracts, and keywords must contain both Thai and English. These English and Thai manuscripts are prepared in A4-sized Microsoft Word documents with leaving 2.54-cm (1-inch) margins on all sides. All documents are required to be aligned left and double-spaced throughout the entire manuscript. The text should be typed in 12-point regular Times New Roman font for English manuscript and 16-point regular TH SarabunPSK font for Thai manuscript.

The running titles of English and Thai manuscripts are placed in the top left-hand corner of each page. They cannot exceed 50 characters, including spaces between words and punctuation. For the header of English paper, the running title will be typed in all capital letters. The page number goes on the top right-hand corner.

Footnotes are not used in the manuscripts, but parenthetical statements within text are applied instead and sparingly. Abbreviations should be defined at first mention and thereafter used consistently throughout the article. The standard abbreviations for units of measure must be used in conjunction with numbers.

All studies that involve human subjects should not mention subjects' identifying information (e.g. initials) unless the information is essential for scientific purposes and the patients (or parents or guardians) give written informed consent for publication.

2. Title Page

The title page is the first page of the manuscripts and must contain the following:

- The title of the paper (not more than 150 characters, including spaces between words)
- The full names, institutional addresses, and email addresses for all authors (If authors regard it as essential to indicate that two or more co-authors are equal in status, they may be identified by an asterisk symbol with the caption "These authors contributed equally to this work" immediately under the address list.)
- The name, surname, full postal address, telephone number, facsimile number, and email address of the corresponding author who will take primary responsibility for communication with AAP.
- Conflict of interest statement (If there are no conflicts of interest for any author, the following statement should be inserted: "The authors declare that they have no conflicts of interest with the contents of this article.")

3. Abstract

A structured form of abstract is used in all Original Article manuscripts and must include the following separate sections:

- *Background: The main context of the study*
- *Objective: The main purpose of the study*
- *Materials and Methods: How the study was performed*
- *Results: The main findings*
- *Conclusions: Brief summary and potential implications*
- *Keywords: 3 – 5 words or phrases (listed in alphabetical order) representing the main content of the article*

4. Introduction

The Introduction section should clearly explain the background to the study, its aims, a summary of the existing literature and why this study was necessary or its contribution to the field.

5. Materials and Methods

The Materials and Methods section must be described in sufficient detail to allow the experiments or data collection to be reproduced by others. Common routine methods that have been published in detail elsewhere should not be described in detail. They need only be described in outline with an appropriate reference to a full description. Authors should provide the names of the manufacturers and their locations for any specifically named medical equipment and instruments, and all chemicals and drugs should be identified by their systematic and pharmaceutical names, and by their trivial and trade names if relevant, respectively. Calculations and the statistical methods employed must be described in this section.

All studies involving animal or human subjects must abide by the rules of the appropriate Internal Review Board and the tenets of the recently revised Helsinki protocol. Hence, the manuscripts must include the name of the ethics committee that approved the study and the committee's reference number if appropriate.

6. Results

The Results section should concisely describe the findings of the study including, if appropriate, results of statistical analysis which must be presented either in the text or as tables and figures. It should follow a logical sequence. However, the description of results should not simply repeat the data that appear in tables and figures and, likewise, the same data should not be displayed in both tables and figures. Any chemical equations, structural formulas or mathematical equations should be placed between successive lines of text. The authors do not discuss the results or draw any conclusions in this section.

7. Discussion

The Discussion section should focus on the interpretation and the significance of the findings against the background of existing knowledge. The discussion should not repeat information in the results. The authors will clearly identify any aspects that are novel. In addition, there is the relation between the results and other work in the area.

8. Conclusion

The Conclusion section should state clearly the main summaries and provide an explanation of the importance and relevance of the study reported. The author will also describe some indication of the direction future research should take.

9. Acknowledgements

The Acknowledgements section should be any brief notes of thanks to the following:

- *Funding sources*
- *A person who provided purely technical help or writing assistance*
- *A department chair who provided only general support*
- *Sources of material (e.g. novel drugs) not available commercially*

Thanks to anonymous reviewers are not allowed. If you do not have anyone to acknowledge, please write "Not applicable" in this section.

10. References

The Vancouver system of referencing should be used in the manuscripts. References should be cited numerically in the order they appear in the text. The authors should identify references in text, tables, and legends by Arabic numerals in parentheses or as superscripts. Please give names of all authors and editors. The references should be numbered and listed in order of appearance in the text. The names of all authors are cited when there are six or fewer. When there are seven or more, only the first three followed by "et al." should be given. The names of journals should be abbreviated in the style used in Index Medicus (see examples below). Reference to unpublished data and personal communications should not appear in the list but should be cited in the text only (e.g. A Smith, unpubl. Data, 2000).

- *Journal article*
  1. Sibai BM. Magnesium sulfate is the ideal anticonvulsant in preeclampsia – eclampsia. Am J Obstet Gynecol 1990; 162: 1141 – 5.
- *Books*
  2. Remington JS, Swartz MN. Current Topics in Infectious Diseases, Vol 21. Boston: Blackwell Science Publication, 2001.

- *Chapter in a book*

  3. Cunningham FG, Hauth JC, Leveno KJ, Gilstrap L III, Bloom SL, Wenstrom KD. Hypertensive disorders in pregnancy. In: Cunningham FG, Hauth JC, Leveno KJ, Gilstrap L III, Brom SL, Wenstrom KD, eds. Williams Obstetrics, 22nd ed. New York: McGraw-Hill, 2005: 761 – 808.

11. Tables

The tables should be self-contained and complement, but without duplication, information contained in the text. They should be numbered consecutively in Arabic numerals (Table 1, Table 2, etc.). Each table should be presented on a separate page with a comprehensive but concise legend above the table. The tables should be double-spaced and vertical lines should not be used to separate the columns. The column headings should be brief, with units of measurement in parentheses. All abbreviations should be defined in footnotes. The tables and their legends and footnotes should be understandable without reference to the text. The authors should ensure that the data in the tables are consistent with those cited in the relevant places in the text, totals add up correctly, and percentages have been calculated correctly.

12. Figure Legends

The legends should be self-explanatory and typed on a separate page titled "Figure Legends". They should incorporate definitions of any symbols used and all abbreviations and units of measurement should be explained so that the figures and their legends are understandable without reference to the text.

If the tables or figures have been published before, the authors must obtain written permission to reproduce the materials in both print and electronic formats from the copyright owner and submit them with the manuscripts. These also follow for quotes, illustrations, and other materials taken from previously published works not in the public domain. The original resources should be cited in the figure captions or table footnotes.

13. Figures

All illustrations (line drawings and photographs) are classified as figures. The figures should be numbered consecutively in Arabic numerals (Figure 1, Figure 2, etc.). They are submitted electronically along with the manuscripts. These figures should be referred to

specifically in the text of the papers but should not be embedded within the text. The following information must be stated to each microscopic image: staining method, magnification (especially for electron micrograph), and numerical aperture of the objective lens. The authors are encouraged to use digital images (at least 300 d.p.i.) in .jpg or .tif formats. The use of three-dimensional histograms is strongly discouraged when the addition of these histograms gives no extra information.

14. Components

14.1. Letters to the Editor

The Letter to the Editor manuscripts consist of the following order:

- *Title Page*
- *Main Text*
- *References*
- *Table (if needed)*
- *Figure Legend (if needed)*
- *Figure (if needed)*

14.2. Original Articles

The Original Article manuscripts consist of the following order:

- *Title Page*
- *Structured Abstract*
- *Introduction*
- *Materials and Methods*
- *Results*
- *Discussion*
- *Conclusions*
- *Acknowledgements*
- *References*
- *Table (s)*
- *Figure Legend (s)*
- *Figure (s)*

14.3. Review Articles

The Review Article manuscripts consist of the following order:

- *Title Page*
- *Unstructured Abstract*
- *Introduction*
- *Main Text*
- *Conclusions*
- *Acknowledgements*
- *References*
- *Table (s)*
- *Figure Legend (s)*
- *Figure (s)*

14.4. Case Reports

The Case Report manuscripts consist of the following order:

- *Title Page*
- *Unstructured Abstract*
- *Introduction*
- *Case Description*
- *Discussion*
- *Conclusions*
- *Acknowledgements*
- *References*
- *Table (s)*
- *Figure Legend (s)*
- *Figure (s)*

14.5. Case Illustrations

The Case Illustration manuscripts consist of the following order:

- *Title Page*
- *Clinical Presentation or Description*
- *Laboratory Investigations*
- *Discussion*
- *Final Diagnosis*
- *Multiple Choice Questions (MCQs)*
- *Take-Home Messages (Learning Points)*

- *Acknowledgements*
- *References*
- *Correct Answers to MCQs*
- *Table (s)*
- *Figure Legend (s)*
- *Figure (s)*

14.6. Technical Notes

The Technical Note manuscripts consist of the following order:

- *Title Page*
- *Introduction*
- *Main text*
- *Conclusions*
- *Acknowledgements*
- *References*
- *Table (s)*
- *Figure Legend (s)*
- *Figure (s)*

Proofreading

The authors of the accepted manuscripts will receive proofs and are responsible for proofreading and checking the entire article, including tables, figures, and references. These authors should correct only typesetting errors at this stage and may be charged for extensive alterations. Page proofs must be returned within 48 hours to avoid delays in publication.

Revised Manuscripts

In many cases, the authors will be invited to make revisions to their manuscripts. The revised manuscripts must generally be received by the Editorial Board within 3 months of the date on the decision letter or they will be considered a new submission. An extension can sometimes be negotiated with the Editorial Board.

APPENDIX 2
BENEFITS OF PUBLISHING WITH ASIAN ARCHIVES OF PATHOLOGY

Asian Archives of Pathology (AAP) is an open access journal. Open Access makes your works freely available to everyone in the world. It provides a significant boost to the readership of your articles, and has been shown to have an increase in positive influence on citations and reuse. Hence, open-access leads to more recognition for our esteemed authors.

The journal has been sponsored by the Royal College of Pathologists of Thailand. We have the policy to disseminate the verified scientific knowledge to the public on a non-profit basis. Hence, we have not charged the authors whose manuscripts have been submitted or accepted for publication in our journal.

Since AAP is also a peer-reviewed journal, the submitted manuscripts will be reviewed by three members of the Editorial Board or three expert reviewers from different institutions. The decision on these manuscripts is processed very fast without any delay and in shortest possible time. The processing period is 1 – 2 weeks. These decisions of the reviewers are unbiased and the decision (reject, invite revision, and accept) letter coming from the Editorial Board is always conveyed to the authors.

APPENDIX 3
SUBMISSION OF THE MANUSCRIPTS

Step 1: Access www.asianarchpath.com

Step 2: If you did not register before, please create an account first.

Step 3: Login with your username and password.

Step 4: Click the "+ New Submission" button on the upper right-hand side of the page.

Step 5: Proceed to fill up the Submission Form online and follow the directions given therein.

Step 6: Upload your manuscript file (s).

Step 7: Re-check the content of your manuscript (s) and the uploaded file (s) more carefully prior to the submission. If you have submitted your manuscript file (s) incorrectly, you must contact Editor-in-Chief of Asian Archives of Pathology immediately. The Editor-in-Chief can clear the incorrect attempt and allow you another submission.

Step 8: Click the "Submit Manuscript" button under Important Notice.

If you have any further enquiries, please do not hesitate to contact the Journal.

APPENDIX 4
CONTACT THE JOURNAL

The Editorial Office of Asian Archives of Pathology

Department of Pathology, Floor 6, Her Royal Highness Princess Bejaratana Building
Phramongkutklao College of Medicine
317 Rajavithi Road, Rajadevi, Bangkok 10400 Thailand

Telephone: +66 (0) 90 132 2047

Fax: +66 (0) 2 354 7791

Email: editor@asianarchpath.com

APPENDIX 5
SUPPORT THE JOURNAL

Asian Archives of Pathology (AAP) has a mission of disseminating the unbiased and reliable medical knowledge on a non-profit basis. If you consider that this journal is useful for the public, you can support us by submitting your advertisements via the contact information below.

Assistant Professor Dr Chetana Ruangpratheep
The Editorial Office of Asian Archives of Pathology
Department of Pathology, Floor 6, Her Royal Highness Princess Bejaratana Building
Phramongkutklao College of Medicine
317 Rajavithi Road, Rajadevi, Bangkok 10400 Thailand
Telephone: +66 (0) 90 132 2047
Fax: +66 (0) 2 354 7791
Email: editor@asianarchpath.com

Every support, small or big, can make a difference.

Thank you

Assistant Professor Dr Chetana Ruangpratheep
MD, FRCPath (Thailand), MSc, PhD
Editor-in-Chief of Asian Archives of Pathology

ACADEMIC MEETINGS AND CONFERENCES

Announcements of academic meetings and conferences that are of interest to the readers of Asian Archives of Pathology (AAP) should be sent to the Editor-in-Chief at least 3 months before the first day of the month of issue. The contact information is shown below.

Assistant Professor Dr Chetana Ruangpratheep

The Editorial Office of Asian Archives of Pathology

Department of Pathology, Floor 6, Her Royal Highness Princess Bejaratana Building

Phramongkutklao College of Medicine

317 Rajavithi Road, Rajadevi, Bangkok 10400 Thailand

Telephone: +66 (0) 90 132 2047

Fax: +66 (0) 2 354 7791

Email: editor@asianarchpath.com

WHAT IS INSIDE THIS ISSUE?

Letter to the Editor:

Original Article:

Case Report: